


MCV/Q

MEDICAL COLLEGE OF VIRGINIA QUARTERLY
VOLUME ELEVEN • NUMBER THREE • 1975



NUCLEAR MEDICINE
Part II

HOW MUCH ANXIETY

"There is a common tendency in our day, both on the part of professional psychologists and laymen, to look upon anxiety as a negative, destructive, "abnormal" experience, one which must be fought and if possible annihilated...."

O. H. Mowrer¹

Since 1950 the literature on anxiety, both professional and lay, has increased a thousandfold in the form of articles, symposia, reports and scientific exhibits. And virtually all of this output reflects a common presumption—that anxiety is a negative, nonproductive experience. This viewpoint leads naturally to a discussion of how to combat or eliminate anxiety.

But anxiety, as Mowrer implies, has its uses. It can play a positive and constructive role in human development. Without it neither an individual nor a society can grow.

Productive vs. nonproductive anxiety: a matter of degree

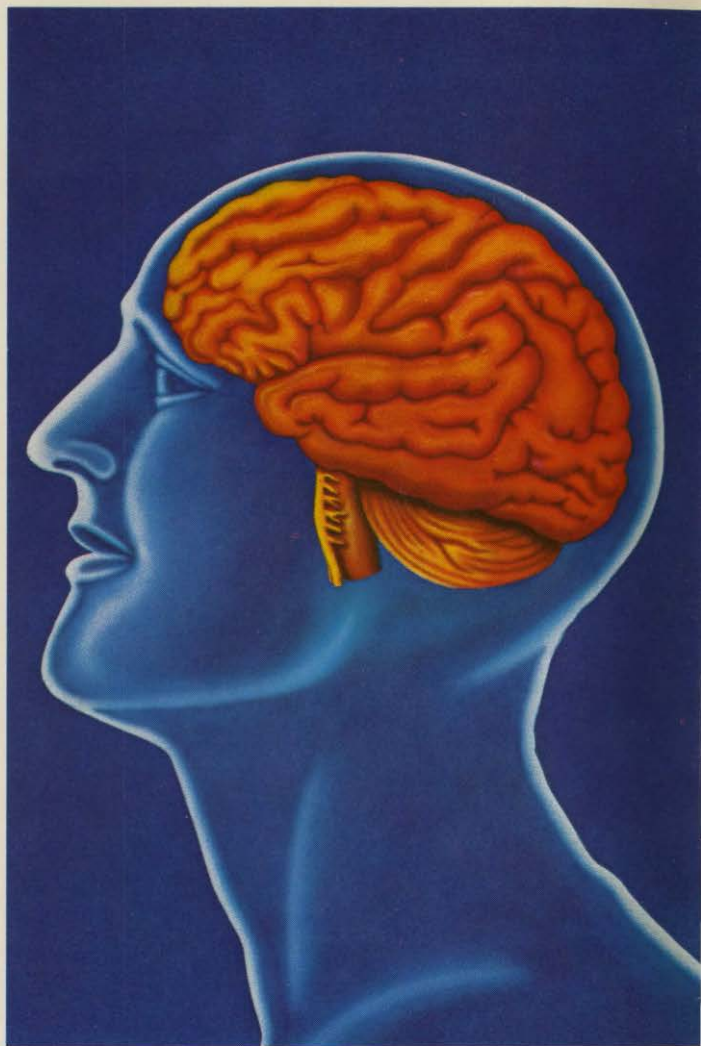
For the physician the difference is not an academic one. He *must* distinguish between productive and nonproductive anxiety. And the difference is often one of degree.

In low levels of anxiety, for example, the individual is alert and sensitive to threats and acquires an increased ability to cope. Performance is often improved.²

But at higher levels of anxiety the opposite is true.² The ability to distinguish between the dangerous and the trivial is reduced and often leads to inappropriate behavior. Apprehension becomes fear. And coping becomes difficult, if not impossible.

Crossing the anxiety threshold

The key question for the physician then becomes: Is the degree of anxiety experienced produc-



tive or nonproductive for the individual patient? And while some patients may require relatively large amounts of anxiety to perform optimally, for others lower levels of anxiety may prove unproductive.

Librium® (chlordiazepoxide HCl): to help lower the level of anxiety

When anxiety has reached levels that seriously

IS PRODUCTIVE?

impair performance, reassurance and counseling may be sufficient for the patient. If not, adjunctive antianxiety medication may be called for.

Librium (chlordiazepoxide HCl), by quickly and effectively calming the anxious patient, helps to lower the level of anxiety. When anxiety has been reduced to manageable levels, therapy with Librium should be discontinued.

Librium® (chlordiazepoxide HCl): an uncomplicated clinical course

To be truly effective, antianxiety medication must allay anxiety without complicating the clinical course. Librium meets this criterion. Librium, when used in proper dosage, rarely interferes with mental acuity. Side effects are seldom encountered. And Librium is used concomitantly with many primary medications.

For a more detailed discussion of the side effects, precautions and warnings, please consult the brief summary of product information on this page.

References: 1. Mowrer OH, quoted in May R: *The Meaning of Anxiety*. New York, Ronald Press Co., 1950, pp. 108 ff. 2. Basowitz H et al: *Anxiety and Stress*. New York, McGraw-Hill, 1955, pp. 12 ff.

LIBRIUM®
chlordiazepoxide HCl/Roche®
5 mg, 10 mg, 25 mg capsules

BASIC IN CLINICAL ANXIETY

Before prescribing, please consult complete product information, a summary of which follows:

Indications: Relief of anxiety and tension occurring alone or accompanying various disease states.

Contraindications: Patients with known hypersensitivity to the drug.

Warnings: Caution patients about possible combined effects with alcohol and other CNS depressants. As with all CNS-acting drugs, caution patients against hazardous occupations requiring complete mental alertness (e.g., operating machinery, driving). Though physical and psychological dependence have rarely been reported on recommended doses, use caution in administering to addiction-prone individuals or those who might increase dosage; withdrawal symptoms (including convulsions), following discontinuation of the drug and similar to those seen with barbiturates, have been reported. Use of any drug in pregnancy, lactation or in women of childbearing age requires that its potential benefits be weighed against its possible hazards.

Precautions: In the elderly and debilitated, and in children over six, limit to smallest effective dosage (initially 10 mg or less per day) to preclude ataxia or oversedation, increasing gradually as needed and tolerated. Not recommended in children under six. Though generally not recommended, if combination therapy with other psychotropics seems indicated, carefully consider individual pharmacologic effects, particularly in use of potentiating drugs such as MAO inhibitors and phenothiazines. Observe usual precautions in presence of impaired renal or hepatic function. Paradoxical reactions (e.g., excitement, stimulation and acute rage) have been reported in psychiatric patients and hyperactive aggressive children. Employ usual precautions in treatment of anxiety states with evidence of impending depression; suicidal tendencies may be present and protective measures necessary. Variable effects on blood coagulation have been reported very rarely in patients receiving the drug and oral anticoagulants; causal relationship has not been established clinically.

Adverse Reactions: Drowsiness, ataxia and confusion may occur, especially in the elderly and debilitated. These are reversible in most instances by proper dosage adjustment, but are also occasionally observed at the lower dosage ranges. In a few instances syncope has been reported. Also encountered are isolated instances of skin eruptions, edema, minor menstrual irregularities, nausea and constipation, extrapyramidal symptoms, increased and decreased libido—all infrequent and generally controlled with dosage reduction; changes in EEG patterns (low-voltage fast activity) may appear during and after treatment; blood dyscrasias (including agranulocytosis), jaundice and hepatic dysfunction have been reported occasionally, making periodic blood counts and liver function tests advisable during protracted therapy.

Supplied: Librium® Capsules containing 5 mg, 10 mg or 25 mg chlordiazepoxide HCl. Libritabs® Tablets containing 5 mg, 10 mg or 25 mg chlordiazepoxide.



Roche Laboratories
Division of Hoffmann-La Roche Inc.
Nutley, New Jersey 07110

CONTENTS

Nuclear
Medicine
Part II

| | | |
|-----|---|---|
| 100 | Introduction KEVIN KAMMERER, M.D. | Introduction KEVIN KAMMERER, M.D. |
| 101 | Scintigraphy in Evaluation of Renal Transplants MARGOT T. HADEN, M.D. | Renal Transplants MARGOT T. HADEN, M.D. |
| 102 | Use of Bone Scanning and Skeletal Radiography in the Diagnosis of Bone Metastases JAY C. MALL, M.D. PAUL E. HOFFER, M.D. | Diagnosis of Bone Metastases JAY C. MALL, M.D. PAUL E. HOFFER, M.D. |
| 110 | Radionucleide Imaging Evaluation of the Patient with Trauma LEONARD M. FARMAN, M.D. LARRY G. LITZKE, M.D. | Radionucleide Imaging Evaluation of the Patient with Trauma LEONARD M. FARMAN, M.D. LARRY G. LITZKE, M.D. |

MEDICAL COLLEGE OF VIRGINIA
QUARTERLY, Volume Eleven, Number Three, Fall 1975, is published by the
Medical College of Virginia, Division of Health Sciences, Virginia Commonwealth
University. The QUARTERLY publishes
results of original research in basic and
clinical sciences. Contributions should be
submitted to the Medical College of Virginia
School of Medicine, Department of
Physiology, Room 100, P.O. Box 9800,
Richmond, Virginia 23298. Manuscripts
should be prepared according to the
instructions in the Style Manual for
Biological Journals, published by the
U.S. American Institute of Biological
Sciences, Second Edition, 1964.

CORRESPONDENCE: MEDICAL COLLEGE
OF VIRGINIA QUARTERLY, Medical
College of Virginia, Richmond, Virginia
23298. Phone 834-2000.

Subscription rates for 1975: Single
copy \$10.00; 1 year \$30.00; 2 years \$50.00;
3 years \$70.00. All rates payable in
advance. Single copies \$10.00; 1 year
\$30.00; 2 years \$50.00; 3 years \$70.00.
Foreign postage and insurance
\$10.00 per year. Single copies \$10.00;
1 year \$30.00; 2 years \$50.00; 3 years
\$70.00. Payment in advance. Single
copies \$10.00; 1 year \$30.00;
2 years \$50.00; 3 years \$70.00.

Printed and bound by Richmond
Virginia.

Editorial Advisory Board:
John T. Fallon
Harold H. Mattingly
M. Thomas Mathias
L. Bruce Rosen
Richard L. Shuman

Editorial Consultant:
Larry J. Cantow, Boston
Richard D. Laxton, Boston
Robert F. Lamb, Dallas
Michael S. Tomer, St. Louis

Editor:
Richard G. Litzke, M.D.
Managing Editor:
Kary-Faye Johnson
Lynn Foster
Elizabeth A. Gray

MCV/Q

MEDICAL COLLEGE OF VIRGINIA QUARTERLY

*A Scientific Publication of the School of Medicine
Health Sciences Division of Virginia Commonwealth University*

1975 • Volume Eleven • Number Three

MEDICAL COLLEGE OF VIRGINIA QUARTERLY Published quarterly (Spring, Summer, Fall, Winter), by the Medical College of Virginia, Division of Health Sciences, Virginia Commonwealth University. The QUARTERLY publishes results of original research in basic and clinical sciences. Contributions from outside the Medical College of Virginia faculty are invited. Manuscripts, submitted in duplicate, should be prepared according to recommendations in the Style Manual for Biological Journals, Washington, D.C., American Institute of Biological Sciences, Second Edition, 1964.

Correspondence: MEDICAL COLLEGE OF VIRGINIA QUARTERLY, Medical College of Virginia, Richmond, Virginia 23298. Phone 804/770-4027.

Subscription rates for U.S.A., Canada, and Mexico: 1 year, \$6.00; 2 years, \$10.00; 3 years, \$14.00. All other countries: 1 year, \$8.00; 2 years, \$12.00; 3 years, \$15.00. Libraries and institutions: (U.S.A.) 1 year, \$12.00; 2 years, \$20.00; 3 years, \$28.00; (*foreign*) 1 year, \$13.00; 2 years, \$21.00; 3 years, \$29.00. Interns, residents, and students: 1 year, \$3.00. Single issue: \$2.00.

Third class postage paid at Richmond, Virginia.

Editorial Advisory Board

John T. Farrar
Hunter H. McGuire
M. Pinson Neal, Jr.
Kinloch Nelson
Frederick J. Spencer

Editorial Consultants

Larry F. Cavazos *Boston*
Richard G. Lester *Durham*
Sami I. Said *Dallas*
Malcolm E. Turner, Jr. *Birmingham*

Editor

Fairfield Goodale, Jr.
Managing Editor
Mary-Parke Johnson
Cover Design
Raymond A. Geary

CONTENTS

NUCLEAR MEDICINE—PART II

A Postgraduate Course in Nuclear Medicine sponsored by the Department of Radiology, Medical College of Virginia, Health Sciences Division of Virginia Commonwealth University

KLAUS RANNIGER, M.D., *Guest Editor*
ALTON R. SHARPE, JR., M.D., *Associate Guest Editor*

Introduction 100
KLAUS RANNIGER, M.D.

Scintiphotography in Evaluation of Renal Transplants 101
HALCOTT T. HADEN, M.D.

Use of Bone Scanning and Skeletal Radiography in the 108
Diagnosis of Bone Metastasis
JAY C. MALL, M.D.
PAUL B. HOFFER, M.D.

Radionuclide Imaging Evaluation of the Patient with Trauma 116
LETTY G. LUTZKER, M.D.
LEONARD M. FREEMAN, M.D.

Scintiphotography in Evaluation of Renal Transplants

HALCOTT T. HADEN, M.D.

INTRODUCTION

In this issue, the MCV Quarterly continues to publish articles on renal transplantation. The first article, by Dr. Haden, discusses the use of scintiphotography in the evaluation of renal transplants. The second article, by Dr. Hoffer, discusses the use of radioimmunoassay in the diagnosis of malignant diseases in renal transplants. The third article, by Dr. Freeman, discusses the use of scintiphotography in the evaluation of renal transplants. The fourth article, by Dr. Haden, discusses the use of scintiphotography in the evaluation of renal transplants.

Radioimmunologic Methods for Diagnosis of Malignant Diseases 128
PAUL B. HOFFER, M.D.

Pitfalls and Artifacts in Nuclear Imaging Studies 131
LEONARD M. FREEMAN, M.D.

© 1975 by the Medical College of Virginia, Health Sciences Division of Virginia Commonwealth University
Printed by the William Byrd Press, Richmond, Virginia

evaluation of renal transplants and for detection of some of the more frequent complications (2,3,4,5). Because of this, scintiphotography now has a major role in transplant evaluation. This paper will review the radioimmunoassay procedures available and their current use in the evaluation of renal transplants.

Scintigraphic Procedures. The transplanted kidney is completely placed in the iliac fossa. This location allows the kidney, aorta, and bladder to be included in the field of view of a standard scintillation camera. The procedures currently in use are: 1. kidney and bladder scintigraphy using ¹²⁵I-orthoiodohippurate.

2. scintigraphy of blood flow distribution followed by kidney and bladder imaging using ¹²⁵I-to-Sa-DTPA.

3. scintigraphy using ¹²⁵I-iodofluoridol.

Presented by Dr. Haden at the Postgraduate Course in Nuclear Medicine, February 27, 1975, in Williamsburg, Virginia.

scintiphotography. Scintiphotography is a technique for obtaining images of the distribution of a radioactive tracer in the body. It is a combination of scintigraphy and photography. The tracer is injected into the body and its distribution is imaged by a scintillation camera. The resulting image is then photographed on a film. This technique is used in the evaluation of renal transplants. The first article in this issue, by Dr. Haden, discusses the use of scintiphotography in the evaluation of renal transplants. The second article, by Dr. Hoffer, discusses the use of radioimmunoassay in the diagnosis of malignant diseases in renal transplants. The third article, by Dr. Freeman, discusses the use of scintiphotography in the evaluation of renal transplants. The fourth article, by Dr. Haden, discusses the use of scintiphotography in the evaluation of renal transplants.

Scintigraphy with ¹²⁵I-iodofluoridol. Currently, iodofluoridol tracers are not commercially compounded in the country. However, when the changes of chronic rejection develop, out-of-label tracers are localized to specific renal

INTRODUCTION

In this issue, the *MCV Quarterly* continues to publish selected papers presented at the recent Postgraduate Course in Nuclear Medicine sponsored by the Department of Radiology of the Medical College of Virginia. The papers reflect modern in vitro and in vivo radioactive isotope applications. Once again the authors deserve our thanks for their enlightening contributions.

KLAUS RANNIGER, M.D.
*Professor and Chairman
Department of Radiology
Medical College of Virginia
Virginia Commonwealth University*

Associate Guest Editor

MEDICAL COLLEGE OF VIRGINIA QUARTERLY - Published Spring, Summer, Fall, Winter

Medical College of Virginia, Health Sciences, Virginia Commonwealth University. The QUARTERLY presents original research in the various sciences. Contributions should be prepared according to the instructions in the *Style Manual for Biological Journals*, Washington, D.C., National Institute of Biological Sciences, Second Edition, 1964.

Subscription rates for 1968: Canada and Mexico: 1 year, \$8.00; 2 years, \$16.00; 3 years, \$24.00. All other countries: 1 year, \$8.00; 2 years, \$16.00; 3 years, \$24.00. Libraries and institutions (U.S.A.): 1 year, \$12.00; 2 years, \$24.00; 3 years, \$36.00. (Germany: 1 year, \$14.00; 2 years, \$28.00; 3 years, \$42.00). Interns, residents, and students: 1 year, \$3.00. Single issue: \$2.00.

Third class postage paid at Richmond, Virginia.

Advisory Board
John T. Farrar
Henry G. McGuire
M. Farrow Neal, Jr.
Kirkland Nelson
Frederick J. Spinrad

Editorial Council
Leroy F. Carrison, Editor
Richard G. Lester, Director
Paul E. Reid, Editor
Malcolm E. Turner, Jr., Birmingham

Editor
Faircliff Goodale, Jr.
Managing Editor
Mary-Doris Johnson
Cover Design
Raymond A. Gray

| | |
|--|-----|
| Introduction KLAUS RANNIGER, M.D. | 100 |
| Scintigraphy in Evaluation of Renal Transplants HALCOTT T. HADEN, M.D. | 101 |
| Use of Bone Scanning and Skeletal Radiography in the Diagnosis of Bone Metastasis JAY C. MALL, M.D. PAUL B. HOFFER, M.D. | 104 |
| Radioisotope Imaging Evaluation of the Patient with Trauma LETTY G. LUTHERS, M.D. LEONARD M. FREEMAN, M.D. | 116 |

Scintiphotography in Evaluation of Renal Transplants

HALCOTT T. HADEN, M.D.

Associate Professor of Radiology and Medicine, Chief, Nuclear Medicine Section, McGuire VA Hospital, Richmond, Virginia

Renal transplantation has progressed from the research stage to become a standard clinical procedure. Although still generally limited to large medical centers, renal transplants are regularly done in over 135 hospitals in the United States. In 1972, approximately 2,600 renal transplants were recorded in the United States by the Renal Transplant Registry (1). Approximately 65% of these were cadaver donors and 35% living donors.

The kidney transplant recipient is subject to a variety of complications, especially during the early post-transplant period. Radionuclide scintiphotography has been found to be a valuable method for evaluation of renal transplant function and for detection of some of the more frequent complications (2,3,4,5). Because of this, scintiphotography now has a major role in transplant evaluation. This paper will review the radionuclide procedures available and their current use in evaluation of renal transplants.

Scintigraphic Procedures. The transplanted kidney is routinely placed in the iliac fossa. This location allows the kidney, ureter, and bladder to be included in the field of view of a standard scintillation camera. The procedures currently in use are:

1. kidney and bladder scintigraphy using ^{131}I -orthoiodohippurate.
2. scintigraphy of blood flow distribution followed by kidney and bladder imaging using $^{99\text{m}}\text{Tc-Sn-DTPA}$.
3. scintigraphy using $^{99\text{m}}\text{Tc-sulfur}$ colloid.

4. scintigraphy combined with transplant renogram or other function studies.

Iodine-131-hippurate scintigraphy. Scintiphotos of the kidney and bladder area are obtained approximately every 4 minutes for 20 to 30 minutes. If the bladder is filled, the patient then voids or the catheter is unclamped and a post-voiding picture is obtained. In a normal study there should be uniform maximum concentration in the renal parenchyma at 4 minutes with excretion into the bladder at 8 minutes and decreasing renal concentration by 20 minutes. Figure 1 shows an example of a normal study.

Perfusion sequence and scintigraphy with $^{99\text{m}}\text{Tc-Sn-DTPA}$. This tracer is excreted exclusively by glomerular filtration and is not as rapidly cleared from plasma as is hippurate. Sufficient radioactivity can be given to visualize the major vessels and renal perfusion if rapid sequential scintiphotos are obtained immediately after a bolus injection. A normal study of this type is seen in Figure 2. If renal function is good, there will be rapid excretion of the tracer and subsequent scintiphotos will show the kidney and urinary tract as seen in Figure 3. If renal function is moderately impaired, however, excretion becomes markedly delayed and may not be adequate for visualization. Hippurate may still give adequate visualization in this case, so that hippurate remains the most dependable tracer for routine use, even though Tc-Sn-DTPA may in some cases give better visualization.

Scintigraphy with $^{99\text{m}}\text{Tc-sulfur}$ colloid. Colloidal tracers are not normally concentrated in the kidney. However, when the changes of chronic rejection develop, colloidal tracers are localized to some extent

Presented by Dr. Haden at the Postgraduate Course in Nuclear Medicine, February 27, 1975, in Williamsburg, Virginia.

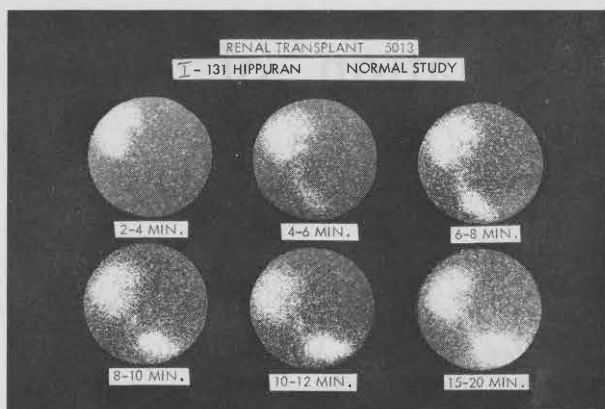


Fig 1—Normal scintiphotographic transplant study using ^{131}I -hippurate. Kidney is seen in first picture and ureter and bladder are visualized in later pictures. Time periods are indicated.

in the kidney and can be demonstrated on scintiphotography. One technique is to use a diverging collimator so as to include the bony pelvis but exclude the liver image (6). The concentration in the kidney is then compared with that in the bones. An example of this study in two separate patients is shown in Figure 4. Both patients had mild to moderate chronic rejection but well-preserved renal function. We have not found this study to be very useful since it does not dependably detect acute rejection and almost all of the transplants eventually develop some degree of chronic rejection.

Scintigraphy combined with renogram or other function studies. Scintigraphy with ^{131}I -hippurate provides only a crude and semiquantitative measure

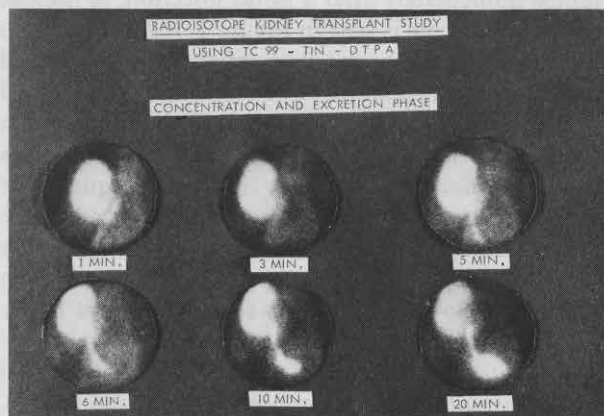


Fig 3—Normal scintigraphic transplant study of excretion phase using $^{99\text{m}}\text{Tc}$ -Sn-DTPA. Kidney, ureter, and bladder are clearly seen.

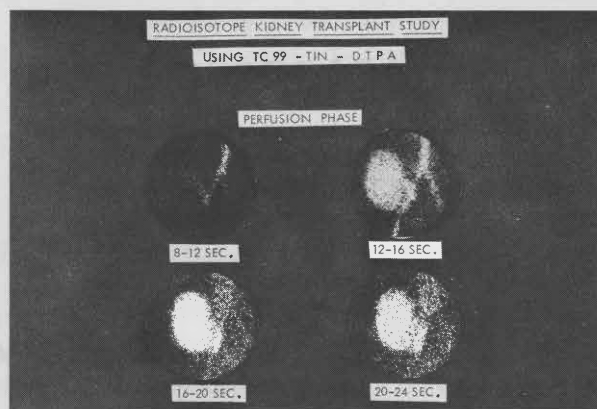


Fig 2—Scintiphotos from a transplant perfusion study using $^{99\text{m}}\text{Tc}$ -Sn-DTPA. Terminal aorta, iliac arteries, and transplanted kidney are seen.

of renal function. A transplant renogram can be obtained simultaneously and gives an additional method of comparing serial studies but is cumbersome to obtain with standard equipment. If the intravenous dose is precisely measured and subsequent blood and urine collection are made, the effective renal plasma flow may be calculated. The value of these additional measurements is not established and they are not routinely used.

Disorders of Transplant Function. The main criterion for satisfactory transplant function is an adequate urine output. Serious complications are usually manifested by a decrease in urine output.

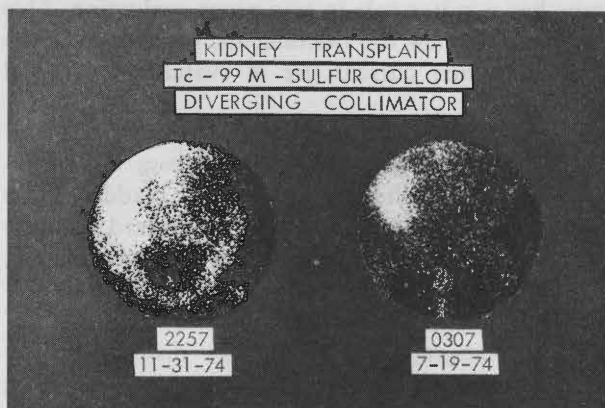


Fig 4—Scintiphotos of transplanted kidney after I.V. injection of $^{99\text{m}}\text{Tc}$ -sulfur colloid. Two separate patients. On the left, concentration is seen in the lumbar spine, pelvis, and in the kidney in the right iliac fossa. On the right, the kidney concentration is so much greater than the bones that pelvis, spine, and upper femur are only very faintly seen.

Table 1 gives a list of the common causes of acute oliguria in transplant recipients. When oliguria occurs, the cause must be promptly determined as a guide to effective treatment.

Acute tubular necrosis is the most common cause of acute oliguria following soon after transplantation, especially with cadaver transplants, and is completely reversible with adequate treatment. If associated with the transplant procedure, this complication occurs within the first 48 hours after surgery. Acute rejection, obstructing clots, and ureteral leaks are also common. Arterial and venous occlusion are uncommon, and we have not yet had cortical necrosis occur. Lymphocele is a collection of lymph adjacent to the transplanted kidney which may occur following interruption of lymphatics in that area. Lymphoceles usually cause compression or displacement of the ureter and bladder and may produce urinary obstruction. They do not occur until after the first week and may not develop until six to eight months after transplantation.

Diagnostic Studies for Acute Oliguria. The various causes of oliguria listed in Table 1 cannot be differentiated on a clinical basis. Prompt diagnosis is obviously of critical importance since the treatment for each cause is different and may entail additional risk. The order of diagnostic studies used by M. J. V. Smith, MD, of the Medical College of Virginia Urology Division is given in Table 2 (7) (oral communication, February, 1975).

The first item on this list, the one-hour biopsy, refers to a kidney biopsy obtained at the end of the

TABLE 1
Causes of Acute Oliguria in Renal Transplant

| |
|-------------------------|
| Vascular |
| Arterial thrombosis |
| Venous thrombosis |
| Parenchymal |
| Acute tubular necrosis |
| Acute rejection |
| Cortical necrosis |
| Ureter |
| Clots |
| Leaks |
| Edema at anastomosis |
| Necrosis and retraction |
| Bladder |
| Leaks or perforations |
| General |
| Lymphocele |

TABLE 2
Acute Oliguria in Renal Transplant
Order of Diagnostic Studies

- | | |
|----|------------------------|
| 1. | one-hour biopsy |
| 2. | irrigate catheter |
| 3. | KUB x-ray |
| 4. | scintigram |
| 5. | cystogram |
| 6. | cystoscopy |
| | a. bulb retrograde |
| | b. catheter retrograde |
| 7. | arteriography |

transplant procedure. This may show early evidence of acute rejection. The first four steps on this list are without risk and often give sufficient diagnostic information to determine treatment. The subsequent procedures should be performed only if necessary because of added risk, especially since these patients all receive aggressive immunosuppressive therapy.

Scintigraphic Findings in Transplant Disorders. A brief tabulation of the scintigraphic findings in transplant disorders is given in Table 3.

Acute tubular necrosis. With acute tubular necrosis the kidney will still concentrate hippurate in the renal parenchyma, although the concentration is somewhat decreased and maximum concentration is delayed. Typically, no excretion into renal pelvis or

TABLE 3
Scintiphotography of Renal Transplants
Using ¹³¹I-Orthoiodohippurate

| |
|--|
| Normal |
| Uniform maximum concentration in renal parenchyma at 4 minutes |
| Excretion into bladder by 8 minutes |
| Decreasing renal concentration by 20 minutes |
| Acute Tubular Necrosis |
| Delayed concentration |
| No excretion |
| Acute Rejection |
| Delayed concentration |
| Irregular concentration |
| Delayed excretion |
| Acute Tubular Necrosis with Added Rejection |
| Delayed irregular concentration compared with baseline |
| Ureteral Obstruction |
| Retention of tracer proximal to obstruction |
| Ureteral Leak |
| Tracer outside urinary tract |
| Vascular Occlusion—Arterial |
| No activity in kidney |

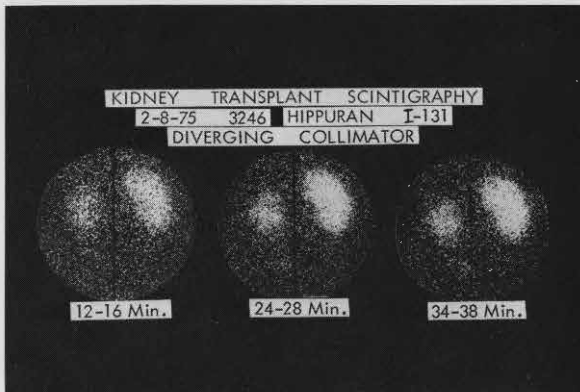


Fig 5—Selected scintigraphs obtained in a patient with two transplanted kidneys studied with ^{131}I -hippurate. Both kidneys are seen. The kidney on the patient's right (observer's left) was transplanted 15 months previously and is the site of severe chronic rejection. The other kidney was inserted one day previously and is not functioning because of acute tubular necrosis.

bladder is visualized. Figure 5 shows pictures selected from a series of scintigraphs obtained because of severe oliguria one day after transplantation of a second kidney into the left iliac fossa. The first kidney was inserted 15 months previously on the right side and had developed severe chronic rejection. The rejected kidney is visualized on the patient's right (observer's left) as an area of poor concentration suggesting a small kidney. The new transplant is well visualized on the patient's left (observer's right), but maximum concentration is definitely delayed and no excretion from the kidney is seen even after 30 minutes. Within a week there was good function of the new kidney.

Rejection. Rejection may be of varying acuteness and severity. Hyperacute rejection occurs immediately after transplantation and is associated with severe acute inflammatory and vascular changes in the kidney. Thrombosis of small vessels occurs, and on scintigraphic study the findings may be the same as in arterial occlusion. The transplanted kidney must always be removed following hyperacute rejection. Rejection of less severity may occur at any time following transplantation. This reaction may develop quite abruptly and may cause sudden oliguria. On scintigraphic study, acute rejection produces delayed and sometimes irregular concentration of hippurate. Excretion is also delayed or may be absent. Figures 6 and 7 show scintigraphic studies of a patient who received a transplant on 5 December, 1974. The scin-

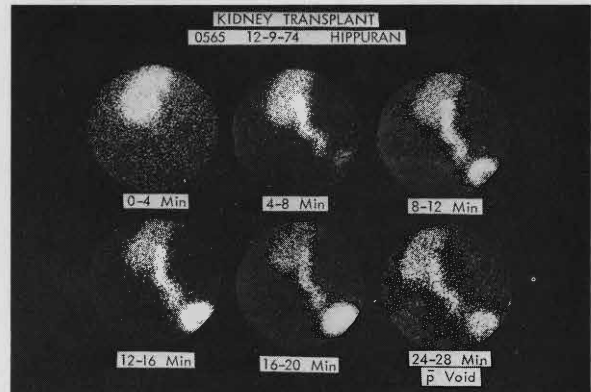


Fig 6—Transplant scintigraphic study four days post-transplant with good function.

tigraphic study on 9 December, 1974, (Fig 6) shows that the kidney is working quite well. On 11 December, 1974, the patient developed sudden oliguria, and a repeat study on that day is shown in Figure 7. Concentration is delayed and there is no excretion. These findings are compatible with either acute tubular necrosis or acute rejection. However, the time after transplantation and the demonstration of good function two days previously exclude acute tubular necrosis resulting from the transplant procedure as a cause of the acute oliguria. This patient was treated for acute rejection with resulting improvement.

Chronic rejection is associated with delayed concentration and delayed excretion as shown in Figure 8. These findings are not specific for chronic rejection since they may occur with other chronic parenchymal disease of the kidney. Concentration of colloidal par-

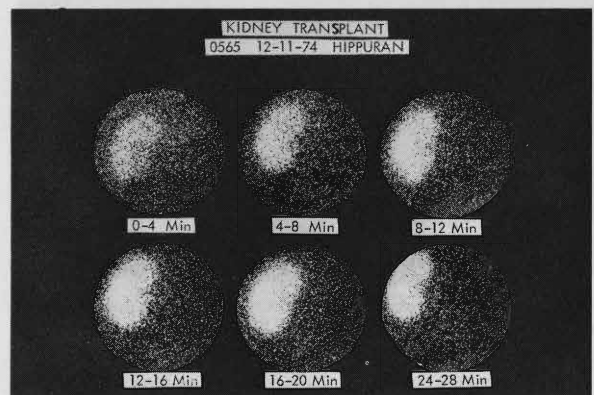


Fig 7—Same patient as Fig. 6 two days later. Acute rejection.

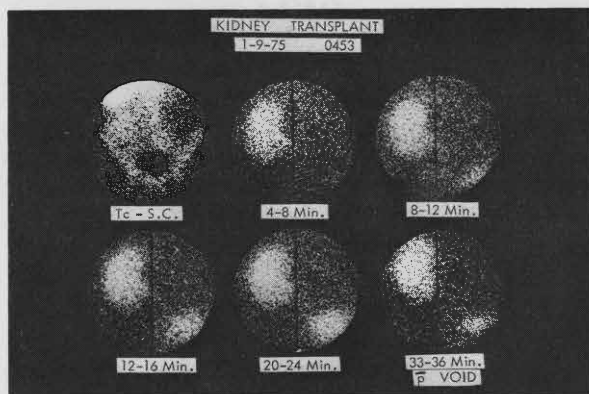


Fig 8—Sulfur colloid and hippurate scintigraphs in chronic rejection.

ticles can be demonstrated in chronic rejection, but this has not been particularly helpful since essentially all of the transplants develop some degree of chronic rejection.

Rejection may be of varying degree and may occur in combination with acute tubular necrosis or other disorders. This may be quite difficult to detect. However, any deterioration of renal function on scintigraphic study after the first 24 hours usually indicates rejection. It is, therefore, good practice to obtain an initial scintigraphic study at 24 to 48 hours after transplantation as a baseline for subsequent studies. Changes due to acute tubular necrosis will be maximal at 24 hours.

Ureteral obstruction. The ureter may be obstructed early by clots or later by stones or by compressing lesions such as lymphoceles. As long as renal parenchymal function remains good there will be good concentration of hippurate by the kidney. Scintigraphic study shows accumulation of tracer proximal to the obstruction with delayed or absent excretion into the bladder. An example of partial obstruction of the upper ureter is shown in Figure 9.

Ureteral leaks. Extravasation of urine from the ureter or from the ureterovesical junction is a common and serious complication of renal transplantation. It has occurred in 8% to 30% of several series with a mortality rate of 25% to 50%. Ureteral leak is readily demonstrable by scintigraphic study, but one must be careful to follow the study long enough to fully evaluate any unusual appearance. It is also wise to obtain post-voiding films to clearly establish bladder location. Figure 10 shows several pictures from a study obtained one month after transplantation. The

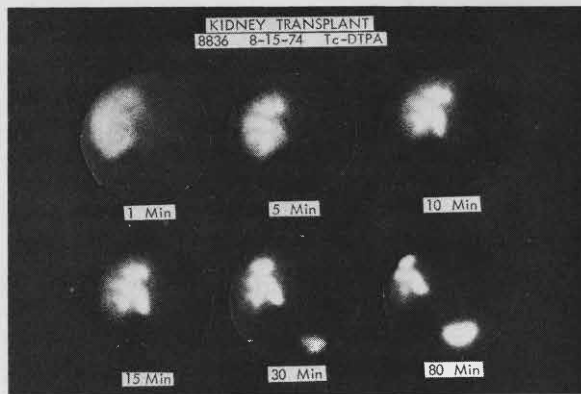


Fig 9—Partial ureteral obstruction producing retention in pelvis and upper ureter, delayed visualization of bladder.

patient had increasing serum creatinine, but no local signs and was thought to have mild rejection. An abnormal collection is seen adjacent to the bladder in the early pictures, and at 25 minutes there is a wide area of abnormal concentration extending along the path of the ureter. The picture at two hours shows the radioactivity located in extravasated urine collected around the bladder, ureter, and lower pole of the kidney. The 10-minute picture also shows some retention of tracer in the renal pelvis and collecting system suggesting mild partial obstruction associated with the urinoma.

Vascular occlusion. With arterial occlusion the kidney is not perfused and no tracer is concentrated in the kidney. Using ^{99m}Tc -pertechnetate or DTPA, the major vessels can be visualized and the lack of perfusion can be demonstrated as shown in the top

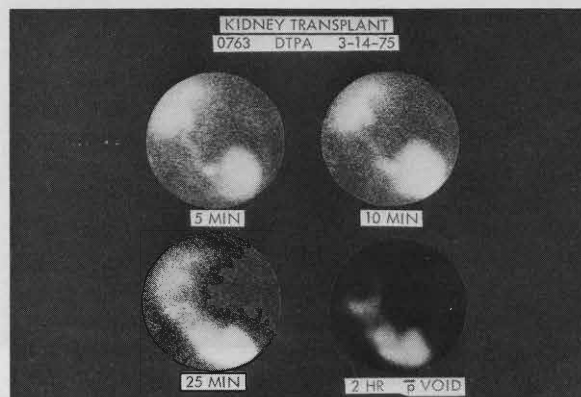


Fig 10—Progressive urine extravasation from ureterovesical junction.

half of Figure 11. When hippurate is the tracer, scintiphotos over the kidney simply show no concentration in the renal parenchyma as at the bottom of Figure 11. These findings may occur in primary arterial occlusion or in hyperacute rejection with thrombosis of small vessels. In either case, surgery is required for removal of the kidney unless a vascular occlusion can be repaired. Venous occlusion, if complete, will block vascular perfusion and is usually followed by thrombosis in the arterial supply. However, venous thrombosis may partially block vascular flow and the kidney may survive after a period of decreased function. If there is viable and perfused renal tissue still present then there should be some concentration of hippurate. It is generally felt, though not completely proven, that the absence of any demonstrable concentration of hippurate indicates that the kidney is no longer viable and should be removed.

Management of Transplant Oliguria Based on Scintigraphic Findings. When oliguria develops in the transplant recipient, the results of the scintigraphic study together with clinical findings will usually indicate the management to be followed. This is briefly summarized in Table 4. If the oliguria develops within the first 48 hours and the scintigram shows a clear renal image with decreased excretion, management for acute tubular necrosis is indicated. If the time period is not compatible with acute tubular necrosis or if subsequent scintigrams show further deterioration, then rejection has developed. If there is no renal image with hippurate or technetium, then

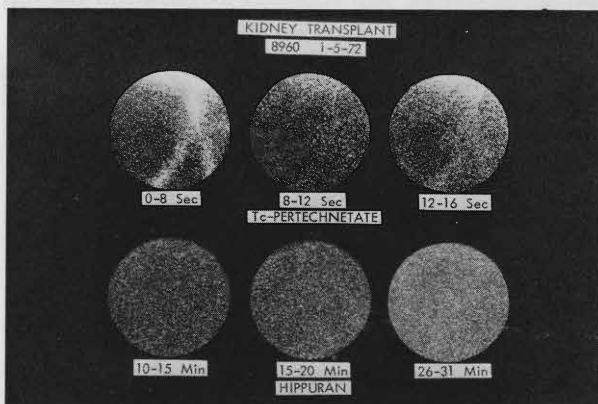


Fig 11—Arterial occlusion. Upper pictures with ^{99m}Tc -pertechnetate show terminal aorta and iliac arteries with “cold” area over kidney. Lower pictures made with ^{131}I -hippurate show no concentration in kidney.

TABLE 4
Hippurate Scintiphotography in Management of Acute Oliguria in Renal Transplants

- | |
|---|
| 1. Clear renal image with decreased excretion: Conservative Management |
| A. If image deteriorates on subsequent study: Treat Rejection |
| 2. No renal image: Study with Pertechnetate Bolus |
| A. If no perfusion: Arteriogram or Surgery |
| 3. Ureteral obstruction: Retrograde or I.V. Urogram or Surgery |
| 4. Extravasation: Retrograde Urogram or Surgery |

surgery is required. An arteriogram can be done if it is necessary to differentiate between hyperacute rejection and arterial occlusion. Ureteral obstruction will usually be evident on the scintigraph, but further diagnostic procedures will be required to determine the cause. Extravasation will also be evident on the scintigraph, but further studies will be required to localize the precise site and extent. In some cases, extravasation can be treated without surgery if infection does not develop.

Conclusions.

1. Scintiphotography of the kidney and bladder using ^{131}I -hippurate is the basic procedure for transplant evaluation. This is a dependable method for determining transplant viability and function. It is also a dependable method for detecting ureteral leak or obstruction, provided that renal function is adequate.
2. Concentration of hippurate indicates that the kidney has a blood supply, is viable, and has recoverable function. Absence of hippurate concentration indicates severe and probably irreversible kidney damage.
3. Scintiphotography with ^{99m}Tc -Sn-DTPA gives good resolution in normally functioning kidneys. With severely impaired renal function, this tracer is inferior to ^{131}I -hippurate.
4. Rapid sequence scintigraphy of the initial circulation using technetium tracers can visualize major vessels and renal perfusion. Quantitation and comparison between studies are difficult.
5. A single scintiphotographic study will not differentiate between acute tubular necrosis and rejection. Serial scintiphotographic

studies may indicate rejection if deterioration of function is shown to occur later than 24 hours after transplantation.

6. Colloidal tracers may concentrate in the kidney in chronic rejection. This phenomenon has not yet been clinically helpful.
7. The scintigraphic findings in transplant disorders have been reviewed and a schema for management based on these findings has been presented.

Figures 1 and 3 are reprinted from the *Journal of Nuclear Medicine*, Vol. 16, No. 7, with permission of publisher.

REFERENCES

1. The 11th report of the Human Renal Transplant Registry, ADVISORY COMMITTEE TO THE RENAL TRANSPLANT REGISTRY. *JAMA* 226:1197-1204, 1973.
2. SALVATIERRA O JR, POWELL MR, PRICE DC, ET AL: the advantages of ¹³¹I-orthoiodohippurate scintiphotography in the management of patients after renal transplantation. *Ann Surg* 180:336-342, 1974.
3. WEISS ER, BLAHD WH, WINSTON MA, ET AL: Scintillation camera in the evaluation of renal transplants. *J Nucl Med* 11: 69-77, 1970.
4. STAAB EV, WHITTIER F, PATTON DD, ET AL: Early evaluation of cadaver renal allotransplant by means of radionuclide imaging. *Radiology* 106:147-151, 1973.
5. ROSENTHALL L, MANGEL R, LISBONA R, ET AL: Diagnostic applications of radiopertechetate and radiohippurate imaging in post-renal transplant complications. *Radiology* 111:347-358, 1974.
6. GEORGE EA, CODD JE, NEWTON WT, ET AL: Visualization of rejecting renal transplants with ^{99m}Tc sulfur colloid (tsc), abstracted. *J Nucl Med* 15:493, 1974.
7. SMITH MJV: Anuria in the recipient, in Hume DH, Rapaport FT (eds): *Clinical Transplantation*, New York, Grune & Stratton, 1973, p. 225-227.

Use of Bone Scanning and Skeletal Radiography in the Diagnosis of Bone Metastasis

JAY C. MALL, M.D. AND PAUL B. HOFFER, M.D.

Department of Radiology, University of California Medical Center, San Francisco, California

The radionuclide bone scan is becoming increasingly useful for evaluating a wide variety of bone and joint disorders. However, the commonest application is still the detection of skeletal metastases in the patient with known or suspected neoplastic disease. The role of this examination relative to other well established methods of evaluating these patients, especially the radiographic skeletal survey, is not clear to all physicians. We hope in this communication to define the role of the radionuclide bone scan and to place in perspective the integral relationship between the "scan" and the "survey," the two radiologic modalities which today are the principal methods of evaluating the skeletal system for metastatic disease.

Radiopharmaceuticals. Historically, numerous agents have been used for bone scanning, but only a small number have been applicable for general clinical use. The first of these were the strontium isotopes, strontium-85 and strontium-87m. Subsequently, fluorine-18 and, most recently, the technetium-99m-labeled phosphate compounds have been used.

Strontium. Strontium is an analogue of calcium and, as such, is incorporated into the hydroxyapatite crystal by an ion-exchange process with calcium (1). Unfortunately, the plasma clearance of strontium is slow due to partial binding with plasma proteins (2, 3). Excretion occurs by both urinary tract and bowel (4).

Strontium-85 nitrate was one of the first agents used for imaging of bone lesions. Its long physical

half-life of 65 days severely limited the administered dose, which was usually 100 microcuries. The presence of bowel activity in the first few days following injection necessitated cleansing enemas and/or long delays between isotope administration and scan. Its 514 keV photon was also much higher than ideal for nuclear imaging instrumentation. Nevertheless, ⁸⁵Sr was a clinically useful bone scanning agent.

Strontium-87m has a considerably shorter physical half-life (2.8 hours) and lower photon energy (388 keV) making it a physically more desirable agent. Unfortunately, the high body-background during the first 12 hours following injection results in less than optimal clinical images (2) and, therefore, this agent has not been widely used for bone imaging.

Fluorine-18. Fluorine-18 is a hydroxyl analogue which is incorporated into bone by an ion-exchange process forming a fluorapatite crystal (1, 5). Bone has a very high affinity for fluorine with most of the radionuclide extracted from the blood on the initial transit (2, 5). The renal extraction efficiency is also high and, therefore, plasma clearance of ¹⁸F is the most rapid of any of the clinically useful bone scanning radionuclides (6,7). Excellent bone-to-background ratios can be obtained with ¹⁸F at 1 to 2 hours following intravenous injection (3, 6). The half-life is very short (1.8 hours) which is advantageous from the standpoint of patient dose. However, the short half-life of ¹⁸F is also a problem because it is cyclotron-produced (8) and, therefore, its use is limited to those locations in close proximity to a cyclotron. The 511 keV annihilation radiation from ¹⁸F makes imaging with the gamma camera difficult. The best images are obtained with a rectilinear scanner or special positron camera (5, 9). Transportation

Presented by Dr. Hoffer at the Postgraduate Course in Nuclear Medicine, February 27, 1975, Williamsburg, Virginia.

problems and cost, both related to the short half-life of ^{18}F , have inhibited its clinical use.

Technetium-99m-labeled compounds. This group of compounds contains the phosphate polymers, pyrophosphate and polyphosphate, and their organic analogues, the diphosphonates. These agents localize

in bone crystal by surface chemisorption rather than ionic exchange (10,11). The terminal phosphate groups of the $^{99\text{m}}\text{Tc}$ -labeled compound react with the "phosphate gaps" which are present in the imperfect bone crystals. (The $^{99\text{m}}\text{Tc}$ acts only as a label unlike ^{18}F and the Sr isotopes). Plasma clearance varies

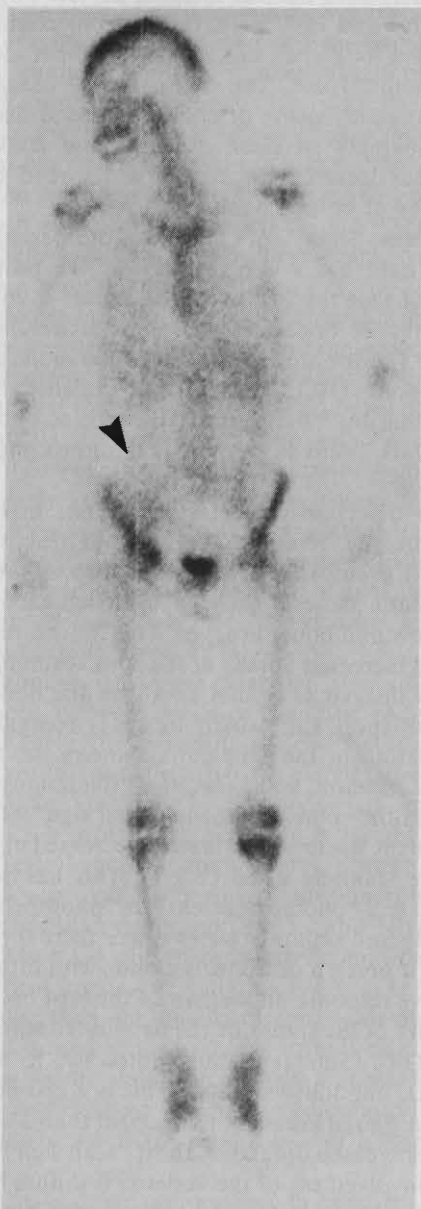


Fig 1—Decreased uptake in Ilium (*arrow*) in patient with metastatic bone lesion. Such "photopenic" lesions occur as a result of lack of hyperemic response to tumor due to debilitation, failure of tumor to provoke response, or radiation to region of lesion.

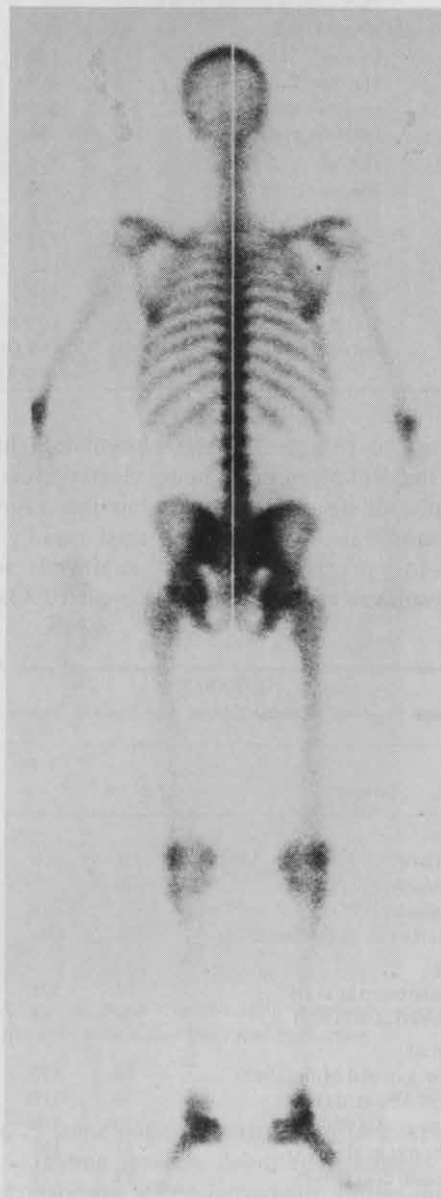


Fig 2—Diffuse increase in skeletal activity denoted by "absence" of renal activity. In addition to diffuse metastasis, the absent kidney sign may also be seen in severe renal disease, hyperparathyroidism and hypermetabolic states.

TABLE 1
Bone Scans vs. Skeletal Survey
for the Detection of Metastatic Lesions to Bone

| Radionuclide | | No. of pts. | +scan -x-ray | -scan +x-ray |
|-------------------|--------------------------|-------------|------------------|-----------------|
| Source | | | | |
| Sr | DeNardo (1966) | 84 | 38% | 4% |
| | DeNardo et al. (1972) | | | |
| | Briggs (1967) | 83 | 20% | 1% |
| | Bessler (1968) | 104 | 15% | 1% |
| | Harmer et al. (1969) | 47 | 41% | 6% |
| | Legge et al. (1970) | 186 | 13% | 2% |
| ¹⁸ F | Gnekow et al. (1972) | 353 | 8% | 2% |
| | Harmer et al. (1969) | 112 | 31% | 3% |
| | Blau et al. (1972) | 239 | 15% | 4.5% |
| | Hopkins et al. (1972) | 104 | 20% | 4% |
| | Merrick (1973) | 119 | 13% | 0 |
| ^{99m} Tc | Desauhiers (1973) | 100 | 9% | 1% |
| | Pendergrass (1973) | 259 | 20% | 2% |
| | Citrin et al. (1974) | 70 | 10% | 0 |
| | Barrett and Smith (1974) | 90 | 71% (of lesions) | 2% |

among the principal agents comprising this group with the diphosphonates being cleared most rapidly, pyrophosphate cleared somewhat less rapidly, and polyphosphates being cleared least rapidly (7). The bone-to-background ratios achieved with the diphosphonates at 3 hours is almost comparable to

TABLE 2
Bone Scan vs. Skeletal Survey For Specific Tumor Types

| Source | # of pts. | +scan -x-ray | -scan +x-ray |
|-----------------------------|-----------|-----------------|-----------------|
| | | | |
| Breast | | | |
| Sklaroff and Charkes (1968) | 64 | 16% | 0 |
| Galasko (1969) | 100 | 29% | 0 |
| Galasko (1971) | | | |
| Marty and Hoffman (1972) | 164 | 26% | — |
| Lung | | | |
| Sauerbrum et al (1972) | 82 | 30% | 0 |
| Shirazi et al (1973) | 206 | 7% | 1% |
| Prostate | | | |
| Morgan and Mills (1968) | 66 | 42% | 0 |
| Williams et al (1968) | 70 | 21% | 0 |
| Roy et al (1971) | 30 | 53% | 0 |
| Shearer et al (1974) | 61 | 12% | 1% |
| Bisson et al (1974) | 81 | 27% | 1% |
| Lymphoma | | | |
| Weber et al (1968) | 19 | 74% | 0 |
| Harbert and Ashburn (1968) | 51 | 12% | 4% |
| Moran et al (1973) | 80 | 5% | 0 |

that achieved with ¹⁸F at 1 to 2 hours (6, 7). Other advantages of this group of agents are the short half-life of ^{99m}Tc (6 hours) which permits the safe administration of millicurie doses and near optimal gamma energy (140 kev) and high photon flux which make possible rapid performance of the procedure and good spatial resolution with the gamma camera, the most widely used nuclear imaging device. The ready availability and easy preparation from commercial kits with a long shelf-life also make them ideal for general clinical use. The ^{99m}Tc-labeled compounds are the current agents of choice for bone scanning. The availability of these excellent and convenient agents has fostered the recent widespread clinical popularity of bone scanning.

"Scans Signs" of Tumor. Considerable laboratory data has accumulated over the past years indicating that the two principal factors involved in the uptake of bone-seeking radionuclides into the bone are 1) bone blood flow and 2) metabolic activity of the bone (10,12,13). Recent evidence has indicated that for ¹⁸F and the ^{99m}Tc-labeled phosphate compounds, bone blood flow is the most important factor (10).

The detection of metastatic tumor in bone is based on the premise that the destructive and reparative events that occur in the bone as a result of a metastatic deposit cause a localized increase in blood flow and bone turnover. This in turn results in localized increased uptake of the bone scanning agent which is imaged as a "hot spot" on the bone scan. This "hot spot" can usually be easily recognized by an alteration in the bilateral symmetry or, as with the axial skeleton, an alteration of the homogeneous uptake in the spine. A second "scan sign" of tumor involvement is a localized area of decreased uptake of the bone scanning agent (Fig 1). This has been referred to as a "photon deficient" or "photopenic" abnormality and occurs in cases where there is replacement of a portion of bone by tumor with little or no reparative response on the part of the host because of the nature of the tumor or the debilitated state of the patient (14). (Similar findings noted by R. S. Hattner, MD, unpublished data.) This is a distinctly less common sign of skeletal involvement than a localized area of increased uptake. A third "scan sign" of metastatic involvement of the skeleton is diffuse but uniform increased uptake which does not alter the bilateral symmetry and may only be recognized by the decrease in renal activity (Fig 2) (15). Normally, the kidneys in adult patients can be clearly identified at

3 to 4 hours following administration of the ^{99m}Tc compounds. The absence of renal activity is a rare but important manifestation of metastatic skeletal involvement which occurs when so much of the radionuclide is deposited in bone that virtually none is available to be localized in the kidney. In some reported series, this "scan sign" was unrecognized and such cases were termed false-negative (16, 17).

Comparison of Bone Scan to Bone Survey. Many clinical studies have been performed comparing the relative sensitivity of the radionuclide bone scan and the radiographic skeletal survey for the detection of skeletal metastases. In earlier reports, ^{85}Sr and $^{87\text{m}}\text{Sr}$ were the isotopes used for radionuclide bone scanning, but in more recent reports ^{18}F and $^{99\text{m}}\text{Tc}$ -labeled phosphate compounds have been employed. These studies are summarized in Table 1 (5, 18-28). All of these studies indicate that the radionuclide bone scan is more sensitive than the radiographic skeletal survey for detecting skeletal metastases. Some reports indicate that the results with $^{99\text{m}}\text{Tc}$ -labeled phosphate compounds are even better than with ^{18}F or the Sr agents (26-31). For certain common neoplasms, a particularly large experience has accrued over the years to compare the two techniques of bone scanning and skeletal survey on a tumor-oriented basis. These comparisons are summarized in Table 2 (32-45) and as noted by E. M. Moran, MD (oral communication, June, 1973).

Although it is quite clear that the radionuclide bone scan is more sensitive than the radiographic skeletal survey for detecting skeletal metastases, it is important to remember that the examination is non-specific in nature. Focal areas of increased radionuclide uptake in bone are invariably due to some skeletal abnormality; however, it must be noted that the scan can be "positive" in numerous conditions other than neoplasm (Fig 3A and 3B) (46, 47). Table 3 is a list of non-neoplastic conditions which cause focal increase in radionuclide uptake in bone. The radiograph, on the other hand, while not as sensitive, is quite specific and may exhibit characteristic patterns which allow for a more accurate etiologic diagnosis. For these reasons, a radiograph is always necessary to assess the significance of a scan abnormality.

False-negative radionuclide bone scans occur infrequently, in approximately 0.4% of patients in most of the recent studies as noted in Tables 1 and 2. These have been seen to occur in certain specific situations (17,48-50). They are: 1) Some patients with

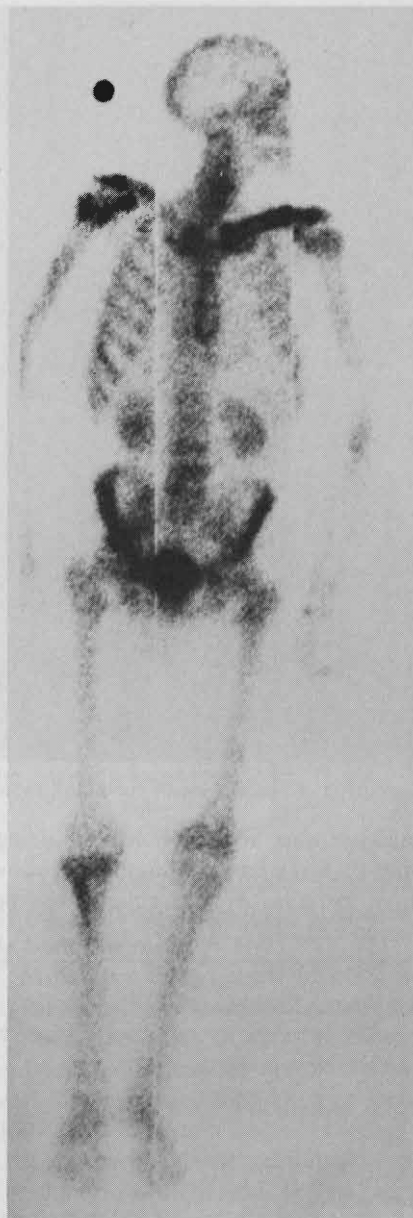

Fig 3A—Abnormal bone scan revealing increased radionuclide uptake in the left clavicle and proximal right tibia.

myeloma; 2) some patients with tumor of anaplastic cell type; 3) some severely debilitated patients with poor host response; 4) patients with diffuse disease uniformly involving the whole skeleton; 5) patients with pelvic lesions obscured by a high level of activity in the bladder; 6) lesions that have been irradiated. As to the incidence of false-positive bone scans, in

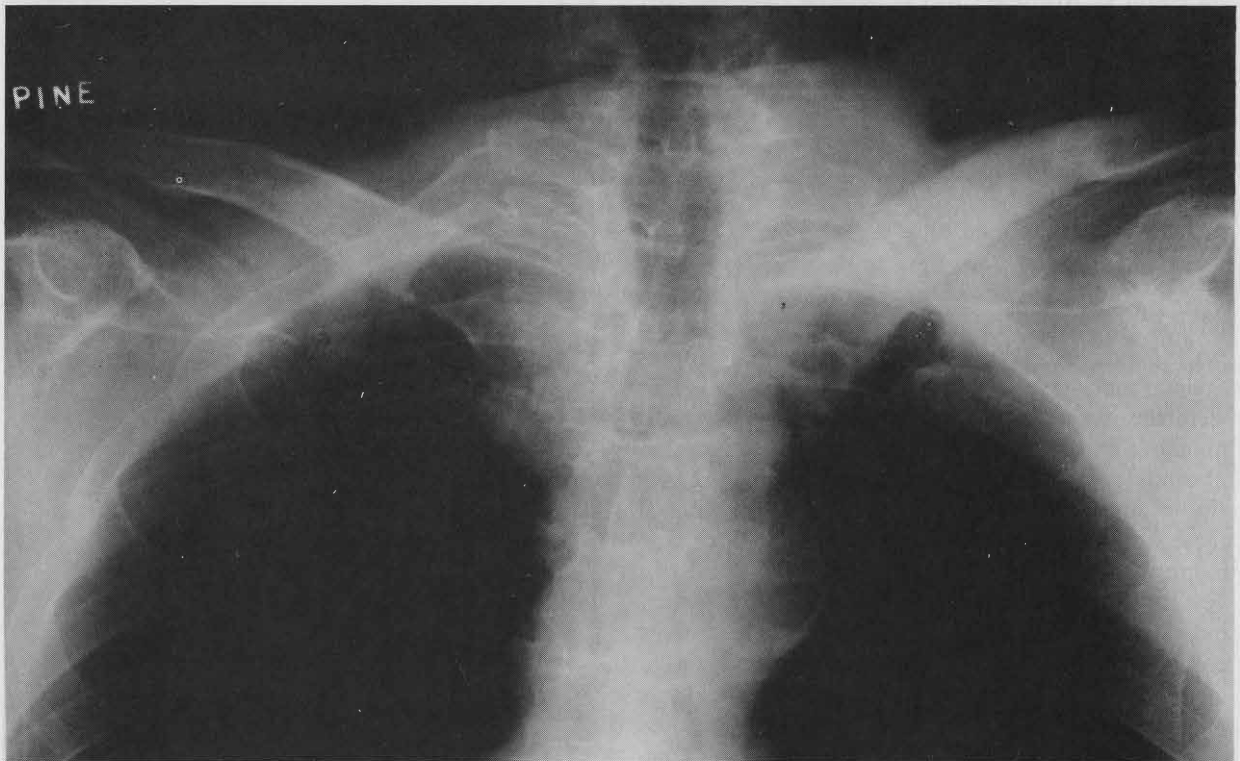


Fig 3B—Radiograph of clavicle reveals coarsened trabecular pattern and sclerosis typical of Paget's disease.

those clinical studies in which lesions detected by scan but not by x-ray were evaluated by follow-up x-rays, biopsy, or autopsy, no actual false-positives have occurred (20,24,39,49).

TABLE 3
Non-Neoplastic Causes of Positive Bone Scan

| | |
|---------------|---|
| Traumatic | |
| | Fracture |
| | Slipped epiphysis |
| Metabolic | |
| | Paget's |
| | Renal osteodystrophy |
| | Hypertrophic pulmonary osteoarthropathy |
| | Gout |
| | Rickets |
| Inflammatory | |
| | Arthritis (any type) |
| | Osteomyelitis |
| | Tendinitis |
| Miscellaneous | |
| | Aseptic necrosis |
| | Osteitis pubis |
| | Hyperostosis frontalis interna |
| | Post-thoracotomy |

The Unified Radiologic Approach. Because of the already high and ever increasing cost of medical care, we need to reassess the manner in which bone scans and radiographs are utilized so that the patient may benefit from minimum waste and duplication of effort. To this end, we have developed a unified radiologic approach to the detection of skeletal metastases (51). An appropriate examination is "tailored" individually for each patient according to the scheme outlined in Figure 4 which is based on an extensive review of the literature as noted above.

Because of the extensive experience in patients with primary neoplasms of breast, lung, and prostate, and also lymphoma, it is reasonable to perform the bone scan as the primary study in these patients. It has even been suggested that the bone scan completely replace the skeletal survey in the evaluation of all patients for skeletal metastases (52). This may shortly come to pass; however, reported experience with primary neoplasms other than those mentioned is not yet great enough. Therefore, we believe that in those patients it is still necessary to perform both complete examinations. It is much more efficient, nevertheless, to perform the scan as the initial study,

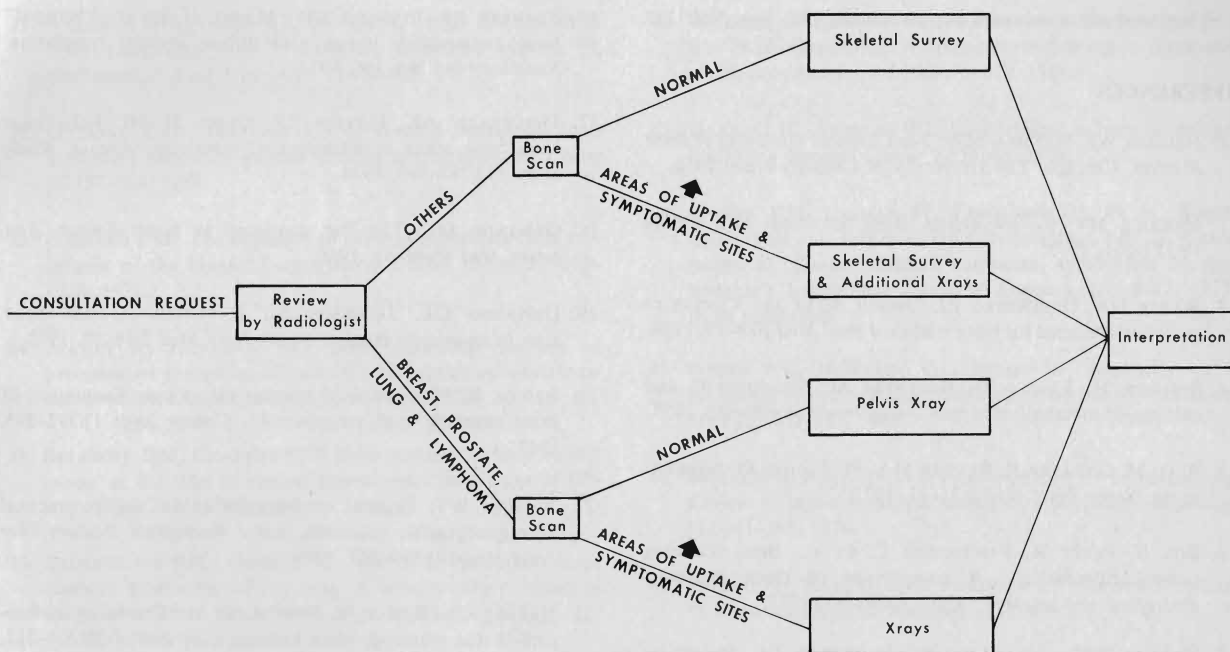


Fig 4—Scheme for radiologic examination of patients with suspected bone metastasis.

even in the latter group. This is because the radionuclide bone scan, as generally performed, is an evaluation of the entire skeleton whereas the radiographic skeletal survey, as generally performed, covers only the axial skeleton. Thus, any sites outside the axial skeleton which may be positive on the scan, can be radiographed at the time the skeletal survey is obtained, thereby eliminating wasted time and effort. This approach is feasible only if false-negative, and to a lesser extent, false-positive bone scans occur infrequently. False-negative scans occur infrequently and usually in specific circumstances as described above. To further minimize this possibility, however, we have incorporated into our approach a radiograph of the pelvis even if the scan is normal. As explained above, false-positive bone scans are, for practical purposes, almost nonexistent.

The efficacy and practicability of the unified approach was determined in a trial period during which it was applied to all patients referred to the radiology department for either radionuclide bone scan or radiographic skeletal survey for the detection of skeletal metastases. A comparison of the individually "tailored" examination actually performed with the examination (or examinations) requested by the clinical service revealed malutilization of these radiologic modalities; that is, superfluous, inadequate

or inappropriate studies were requested in almost half the patients examined (51).

Conclusions.

1. Technetium-99m-labeled phosphate compounds are currently the agents of choice for radionuclide bone scanning.
2. Metastatic involvement of bone is most frequently identified by a localized area of increased uptake. Uncommon signs of skeletal metastasis are a localized area of decreased uptake and generalized symmetrically increased uptake with reduced renal excretion.
3. Radionuclide bone scanning is much more sensitive than the radiographic skeletal survey for the detection of skeletal metastases.
4. Since the findings on the bone scan are non-specific, all abnormal areas should be radiographed to determine the nature of the abnormality.
5. The incorporation of the radionuclide bone scan and the radiographic skeletal survey into a single unified examination for the detection of skeletal metastases, formulated and coordinated by the radiologist, is desirable, practicable, and efficacious.

Table 1 and Table 2 reprinted with permission from *Radiology*, Vol. 117, No. 1.

Figure 4 reprinted with permission of *Radiology*, Vol. 117, No. 1.

REFERENCES

1. NEUMAN WF, NEUMAN MW: *The Chemical Dynamics of Bone Mineral*. Chicago, The University of Chicago Press, 1958.
2. MERRICK MV: Review article. Bone Scanning. *Br J Radiol* 48:327-351, 1975.
3. WEBER DA, GREENBERG EJ, DIMICH A, ET AL: Kinetics of radionuclides used for bone studies. *J Nucl Med* 10:8-17, 1969.
4. SPENCER H, LASZLO D, BROTHERS M: Strontium-85 and calcium-45 metabolism in man. *J Clin Invest* 36:680-688, 1957.
5. BLAU M, GANATRA R, BENDER MA: ^{18}F fluorine for bone imaging. *Semin Nucl Med* 2:31-37, 1972.
6. BOK B, PEREZ R, PANNECIERE C, ET AL: Bone scanning radiopharmaceuticals: A comparison of three products, abstracted. *J Nucl Med* 14(pt 1):380-381, 1973.
7. HUGHES SPF, JEYASINGH K, LAVENDER PJ. Phosphate compounds in bone scanning. *J Bone Joint Surg* 57B:214-216, 1975.
8. HARPER PV, LEMBARES N, KRIZEK H: Production of ^{18}F with deuterons on neon. *J Nucl Med* 12(pt 1):362-363, 1971.
9. BLAU M, LAOR Y, BENDER MA: Isotope scanning with ^{18}F for the early detection of bone tumors. Medical Radioisotope Scintigraphy, Proceedings of a Symposium, Salzburg, Austria, August 1968. IAEA, Vienna, Austria, 1969.
10. GENANT HK, BAUTOVICH GH, SINGH M, ET AL: Bone-seeking radionuclides: An in vivo study of factors affecting skeletal uptake. *Radiology*, 113:373-382, 1974.
11. JUNG A, BISAZ S, FLEISCH H: The binding of pyrophosphate and two diphosphonates by hydroxyapatite crystals. *Calcif Tissue Res* 11:269-280, 1973.
12. BROOKS M, HELAL B: Vascular factors in osteogenesis, in Jelliffe AM, Strickland B (eds): *Symposium Ossium*. London, E & S Livingstone, 1970, pp 129-132.
13. VAN DYKE D, ANGER HO, YANO Y, ET AL: Bone blood flow shown with ^{18}F and the positron camera. *Am J Physiol* 209:65-70, 1965.
14. GOERGEN T, HALPERN S, ALAZRAKI N, ET AL: The "photon deficient" area: A new concept in bone scanning, *J Nucl Med* 15(pt 1):495, 1974.
15. SY WM, PATEL D, FAUNCE H: Significance of absent or faint kidney sign on bone scan, *J Nucl Med* 16:454-456, 1975.
16. FRANKEL RS, JOHNSON KW, MABRY JJ, ET AL: "Normal" bone radionuclide image with diffuse skeletal lymphoma. *Radiology* 111:365-366, 1974.
17. THRUPKAEW AK, HENKIN RE, QUINN JL III. False negative bone scans in disseminated metastatic disease. *Radiology* 113:383-386, 1974.
18. DENARDO GL: The ^{85}Sr scintiscan in bone disease. *Ann Intern Med* 65:44-53, 1966.
19. DENARDO GL, JACOBSON SJ, RAVENTOS A: ^{85}Sr bone scan in neoplastic disease. *Semin Nucl Med* 2:18-30, 1972.
20. BRIGGS RC: Detection of osseous metastases: Evaluation of bone scanning with strontium-85. *Cancer* 20(pt 1):392-395, 1967.
21. BESSLER WT: Skeletal scintigraphy as an aid in practical roentgenographic diagnosis. *Am J Roentgenol Radium Ther Nucl Med* 102:899-907, 1968.
22. HARMER CL, BURNS JE, SAMS A, ET AL: The value of fluorine-18 for scanning bone tumors. *Clin Radiol* 20:204-212, 1969.
23. LEGGE DA, TAUXE WN, PUGH DG, ET AL: Radioisotope scanning of metastatic lesions of bone. *Mayo Clinic Proc* 45:755-761, 1970.
24. HOPKINS GB, KRISTENSEN KAB, BLICKENSTAFF DE: Fluorine 18 bone scans in the detection of early metastatic bone tumors. *JAMA* 222:813-814, 1972.
25. MERRICK MV: Detection of skeletal metastases: A comparison of three radioisotopic techniques using ^{18}F and radiology. *Br J Radiol* 46:968-971, 1973.
26. BARRETT JJ, SMITH PHS: Bone imaging with $^{99\text{m}}\text{Tc}$ polyphosphate: A comparison with ^{18}F and skeletal radiography. *Br J Radiol* 47:387-392, 1974.
27. CITRIN DL, GREIG WR, CALDER JF, ET AL: Preliminary experience of bone scanning with $^{99\text{m}}\text{Tc}$ -labeled polyphosphate in malignant disease. *Br J Surg* 61:73-75, 1974.
28. DESAULNIERS M, LACOURCIERE Y, LISBONA R: A detailed comparison of bone scanning with $^{99\text{m}}\text{Tc}$ polyphosphate and radiographic skeletal surveys for neoplasm. *J Can Assoc Radiol* 24:340-343, 1973.
29. SILBERSTEIN EB, SAENGER EL, TOFE AJ, ET AL: Imaging of bone metastases with $^{99\text{m}}\text{Tc}$ -sn-ehdp (diphosphonate), ^{18}F , and skeletal radiography. *Radiology* 107:551-555, 1973.
30. WEBER DA, KEYES JW JR, LANDMAN S, ET AL: Comparison of $^{99\text{m}}\text{Tc}$ polyphosphate and ^{18}F for bone imaging. *Am J Roentgenol Radium Ther Nucl Med* 121:184-190, 1974.

31. WELLMAN HN, ANGER RT, BROWN A, ET AL: Evaluation of bone malignancy with ^{99m}Tc -sn-ehdp compared with ^{18}F , abstracted. *J Nucl Med* 14(pt 1):464-465, 1973.
32. GALASKO CSB: The detection of skeletal metastases from mammary cancer by gamma camera scintigraphy. *Br J Surg* 56:757-764, 1969.
33. GALASKO CSB: The detection of skeletal metastases from carcinoma of the breast. *Surg Gynecol Obstet* 132(pt 2):1019-1024, 1971.
34. MARTY R, HOFFMAN HC: Bone scanning: Its use in preoperative evaluation of patients with suspicious breast masses, abstracted. *J Nucl Med* 13(pt 1):452, 1972.
35. SKLAROFF DM, CHARKES ND: Bone metastases from breast cancer at the time of radical mastectomy. *Surg Gynecol Obstet* 127(pt 2):763-768, 1968.
36. SAUERBRUNN BJL, HANSEN H, NAPOLI L: Strontium bone scans in carcinoma of the lung: A comparative prospective study, abstracted. *J Nucl Med* 13(pt 1):465-466, 1972.
37. SHIRAZI PH, STERN AJ, SIDELL MS, ET AL: Bone scanning in the staging and management of bronchogenic carcinoma. Review of 206 cases, abstracted. *J Nucl Med* 14(pt 1):451, 1973.
38. BISSON J, VICKERS M JR, FAGAN WT JR: Bone scan in clinical perspective. *J Urol* 111:665-669, 1974.
39. MORGAN C JR, MILLS P: Radioactive bone scans in carcinoma of the prostate. *South Med J* 61(pt 2):785-790, 1968.
40. ROY RR, NATHAN BE, BEALES JSM, ET AL: 18 fluorine total body scans in patients with carcinoma of the prostate. *Br J Urol* 43:58-64, 1971.
41. SHEARER RJ, CONSTABLE AR, GIRLING M, ET AL: Radioisotopic bone scintigraphy with the gamma camera in the investigation of prostatic cancer. *Br Med J* 2:362-365, 1974.
42. WILLIAMS DF, BLAHD WH, WETTERAU L: Radioactive fluorine-18 photoscanning: A diagnostic evaluation in carcinoma of the prostate. *J Urol* 100:675-679, 1968.
43. HARBERT JC, ASHBURN WL: Radiostrontium bone scanning in hodgkin's disease. *Cancer* 22:58-63, 1968.
44. MORAN EM, ULTMAN JT, FERGUSON DJ, ET AL: Staging laparotomy in non-hodgkin's lymphomas. *Br J Cancer* (suppl 2) (Cancer research campaign, symposium on non-hodgkin's lymphomas. London, England, Oct 8-12, 1973), to be published.
45. WEBER WG, DeNARDO GL, BERGIN JJ: Scintiscanning in malignant lymphomatous involvement of bone. *Arch Intern Med* 121:433-437, 1968.
46. SHIRAZI PH, RAYUDU GVS, FORDHAM EW: ^{18}F bone scanning: Review of indications and results of 1,500 scans. *Radiology* 112:361-368, 1974.
47. SHIRAZI PH, RAYUDU GVS, FORDHAM EW: Review of solitary ^{18}F bone scan lesions. *Radiology* 112:369-372, 1974.
48. CHARKES ND, SKLAROFF DM, YOUNG I: A critical analysis of strontium bone scanning for detection of metastatic cancer. *Am J Roentgenol Radium Nucl Med* 96:647-656, 1966.
49. GALASKO CSB, DOYLE FH: The detection of skeletal metastases from mammary cancer. A regional comparison between radiology and scintigraphy. *Clin Radiol* 23:295-297, 1972.
50. SHARMA SM, QUINN JL III: Sensitivity of ^{18}F bone scans in the search for metastases. *Surg Gynecol Obstet* 135(pt 2):536-540, 1972.
51. MALL JC, BEKERMAN C, HOFFER PB, ET AL: A unified approach to the detection of skeletal metastases. (to be published)
52. MERRICK MV: Bone scans or skeletal surveys? *Lancet* 2:382-383, 1973.

Radionuclide Imaging Evaluation of the Patient with Trauma

LETTY G. LUTZKER, M.D.

Assistant Professor of Radiology, Albert Einstein College of Medicine, Bronx, New York

LEONARD M. FREEMAN, M.D.

Associate Professor of Radiology and Co-director of the Division of Nuclear Medicine, Albert Einstein College of Medicine, Bronx, New York

Trauma is now a major medical problem. Accidental injuries constitute the fourth leading cause of death in the United States, and the primary cause of death below the age of 37.

The costs of immediate medical and surgical care, prolonged hospitalization, and lost productivity amount to several billions of dollars annually.

Nuclear medicine techniques have an important place in the evaluation of the injured patient. In general, they are rapid and noninvasive. They can provide functional as well as anatomic information. The sensitivity is often greater than that of routine radiographic procedures, particularly in the evaluation of bone lesions. The accuracy of imaging in evaluating traumatic damage to the skull and abdominal organs approaches or equals that of angiography.

An awareness of the wide range of examinations available to the physician who must evaluate and treat the injured patient is necessary if these extremely useful techniques are to be utilized.

The following discussion will describe

the radionuclide procedures used in diagnosis of trauma and their clinical usefulness. For review of the literature and extensive documentation of the studies and results explained below, the reader is referred to the articles listed at the conclusion of this discussion (1-4). Specific citations will not be made here, except for studies not included in these reviews.

I. Central Nervous System Trauma.

A. Brain Imaging: Radiographic examination of the skull provides minimal information in the patient with head trauma. The presence or absence of linear skull fracture has no demonstrable relationship to the presence of significant intracranial damage (5, 6). Contrast angiography is highly specific and provides high-resolution studies of the intracranial vascular tree and traumatic mass lesions. However, it is expensive and uncomfortable and has a significant morbidity.

Radionuclide studies are more revealing than plain films. They are also less expensive, less uncomfortable, and far less invasive than angiographic procedures and can provide useful information about intracranial blood flow and traumatic damage.

1. Extracerebral hematomas. Subdural hematomas are found in 55% to 70% of patients succumbing to head injuries. Epidural hematomas occur about one-fifth as frequently. The patient with an

From the Division of Nuclear Medicine, Department of Radiology, Albert Einstein College of Medicine, Bronx, New York 10461, and presented by Dr. Freeman at the Postgraduate Course in Nuclear Medicine, February 27, 1975, Williamsburg, Virginia.

acute collection may be too seriously injured to be studied, but imaging studies can be quite useful in the patient with a chronic subdural or, more rarely, chronic epidural hematoma.

In subdural hematoma, caused by rupturing of cerebral veins passing through the subdural space en route to the venous sinuses, the blood first clots and may liquefy in two to four days. A fibrinous pseudomembrane forms during the next ten days, followed by development of a true fibrous membrane by three to four weeks.

The most popular radionuclide for evaluation of cerebral collections is ^{99m}Tc -pertechnetate. More recently, ^{99m}Tc -DTPA, -glucoheptonate, -diphosphonate, and -citrate have been successfully used and in selected cases may prove superior to pertechnetate (7, 8, 9). It is not certain whether the accumulation of nuclide in the subdural fluid or in the membrane accounts for the appearance of activity on the brain scan. Certainly, scans are more likely to be positive late in the course, when membranes are well-developed, than early, before they have formed.

The typical appearance of an extracerebral hematoma is a "hot" crescent seen on anterior and posterior static views, with little or no abnormality on lateral view (Fig 1). The crescent appearance is not specific, and can be seen in many intra- and extracranial lesions, including scalp trauma, skull fracture, craniotomy defect, unilateral Paget's disease, meningitis, cerebral contusion or hematoma, infarct, and tumor. False-positive crescents can be caused by rotation of the head. The intracerebral location of some of these conditions can often be determined on lateral views, where the circumscribed nature of the increased activity can be quite different from the diffuse increase seen in subdural hematoma. Of course, peripheral intracerebral lesions may be difficult to differentiate. Correlation with physical findings, radiography, and dynamic imaging (see below) is necessary in evaluating the crescent sign.

Another, much less common, appearance of a subdural hematoma is the "rim sign," a curvilinear area of increased activity adjacent to an area of decreased activity. It is probably caused by displacement and compression of normal brain by the extracerebral collection.

The appearance of epidural hematomas is less extensively documented because fewer patients have been studied. The patterns appear to be the same as those of subdural hematoma.

Extracranial lesions can often be ruled out or

confirmed by performance of dynamic brain imaging (Fig 1). A bolus of 10 to 15 millicuries of the radionuclide is injected rapidly into a peripheral vein. The Oldendorf technique of arterial occlusion may be used, but is probably not necessary for this purpose. A simple tourniquet and relatively quick injection of a high-activity, low-volume (~1 ml) bolus usually is adequate. The patient's head is positioned under the gamma camera before injection, usually in the anterior position unless a posterior site of injury indicates the need for a posterior study. Images are obtained every 2 to 3 seconds for 15 to 25 seconds. Static images in anterior, posterior, and both lateral positions are then obtained immediately and two to four hours later.

The diagnostic accuracy or sensitivity of the brain scan ranges from approximately 50% during the first ten days after trauma to 90% thereafter. The results in children are somewhat less impressive, in

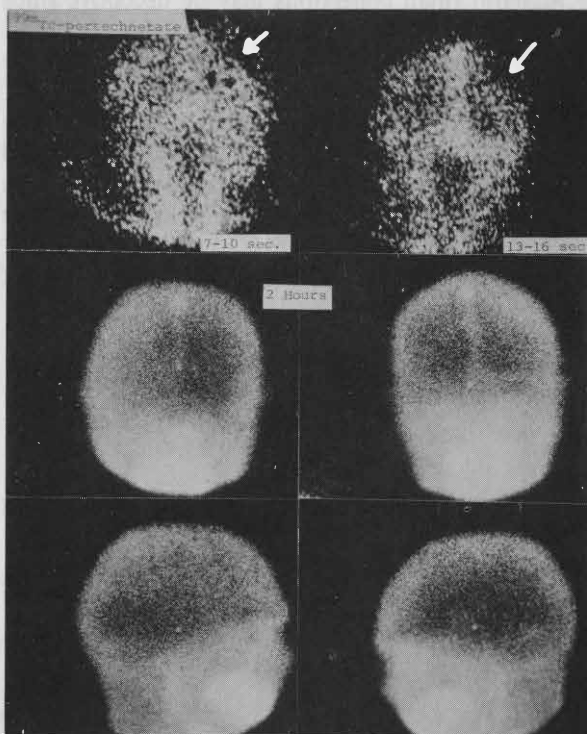


Fig 1—Right subdural hematoma. The initial 2 frames on top are from the early posterior radionuclide angiogram. Note peripheral avascular zone superiorly (arrows). The static views performed 2 hours later show a thickened right vascular rim on the sagittal projections associated with a diffuse increase in activity over the hemisphere on the right lateral view. Compare this latter finding with the normal left lateral view.

the range of 60% to 75%. Dynamic imaging has reportedly raised the diagnostic accuracy of early studies to nearly 100%, but in some series has been positive in only half of proven cases of subdural hematoma. The sensitivity of the examination is improved by obtaining images several hours after injection and repeating equivocal studies after several days. This also decreases the problem of false-positives because of soft tissue scalp trauma, which demonstrates rapidly diminishing activity over several days.

A negative study does not rule out the presence of a small subdural collection. The resolving capabilities of cerebral angiography are unquestionably higher and its sensitivity approaches 100%. Radionuclide imaging should diagnose collections of more than 1 cm in diameter. It may be difficult to appreciate subdural collections by imaging when they are located in the posterior fossa, under the temporal lobe, or in other unusual locations.

Bilateral small collections may be deceptive since the observer cannot compare one side to the other. This is a particular problem in children, in whom bilateral collections are more common than in adults. However, the striking thickness of the vascular rim can suggest the diagnosis (Fig 2). The study should not be called truly negative unless delayed views are obtained and are normal. The incidence of positive scans increases over one to four hours after injection, and equivocal studies can be definitely diagnostic if delayed imaging is performed.

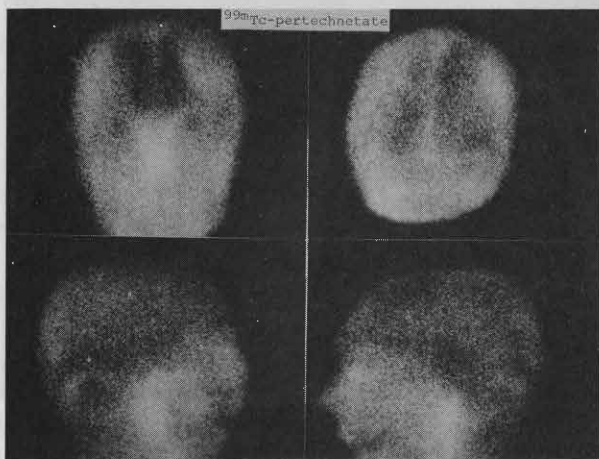


Fig 2—Bilateral subdural hematomas. This static scintiphotographic study was performed 2 hours following injection. Thickening of both vascular rims on the sagittal projections is associated with a diffuse increase in uptake over both hemispheres on the lateral views.

2. *Intracerebral hematoma and contusion.* Few cases of intracerebral hematoma have been reported, probably because the acute nature of the patient's condition often precludes radionuclide evaluation. However, the appearance of a well-defined area of increased activity within the brain, on all projections, has been described. The appearance is indistinguishable from tumor, abscess, or infarct, and the study must be interpreted in context and sometimes repeated. Again, delayed imaging will lead to more positive diagnosis. The sensitivity of the study is about 65% to 75%.

Contusion may present a similar appearance on imaging studies, but no definite mass can be seen when angiography is performed. The scan returns to normal over several weeks. More often, the scan in cases of contusion is normal.

3. *Radionuclide cisternography.* This is a more difficult and invasive procedure than brain scanning, and because of the risk of aseptic meningitis, causes a higher morbidity. However, in certain instances it can reveal very useful information. A small volume containing 0.5 to 1.0 millicuries of $^{111}\text{In-DTPA}$ is introduced directly into the subarachnoid space via lumbar or cisternal puncture. Sequential views in lateral and anterior positions over the spine and skull are necessary.

The study can be used to detect CSF leaks from the spinal canal (10) (Fig 3) or skull. In the latter case, nasal pledgets can be left in place for later counting as an aid in detecting leaks through the frontal sinuses, cribriform plate, sphenoid sinus, and petrous bone. If proper techniques are employed, the accuracy of the procedure is quite high (>90%). After a leak has been seen, rectilinear scanning may be performed for more exact correlation with skull x-rays in determining the surgical approach.

The syndrome of normal-pressure hydrocephalus can occur after traumatically induced subarachnoid bleeding. The mechanism is presumed to be obstruction of usual CSF absorption pathways by adhesions. Abnormal CSF flow patterns can be detected by radionuclide cisternography. Serial imaging at 1, 6, 24, and 48 hours demonstrates filling of dilated ventricles at 24 hours without the normal activity over the hemispheres, and ventricular stasis at 48 hours.

II. Liver and Spleen Injury.

The liver is injured in 5% to 10% of patients suffering blunt abdominal trauma, and is the most commonly injured organ in penetrating abdominal

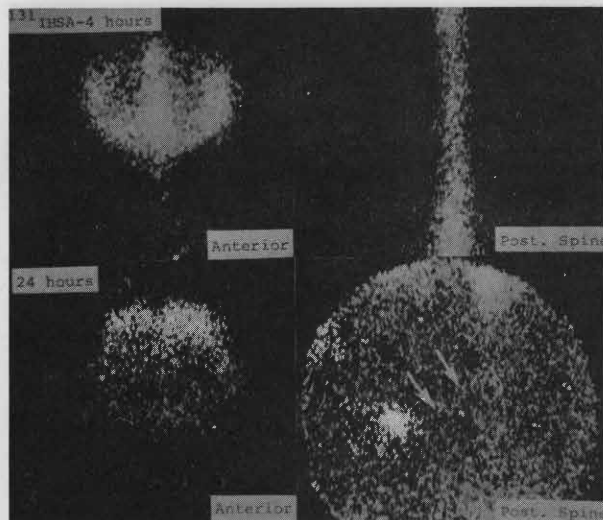


Fig 3—Spinal cerebrospinal fluid leak. The patient was a 50-year-old man who developed right lower extremity weakness following a stab wound of the low back. *Upper Left.* Posterior Anger camera scintiphoto of head 4 hours after intrathecal C1-C2 injection of ^{131}I -Human Serum Albumin shows normal distribution of activity in basal cisterns. *Upper Right.* Posterior view of the dorsolumbar spine at 4 hours shows normal uniform distribution of activity. *Lower Left.* Posterior view of head at 24 hours shows normal progression of tracer over convexity. *Lower right.* Posterior view of lumbosacral spine at 24 hours shows oblique band of activity (arrows) running between subarachnoid space and site of stab wound (hot spot marked by ^{67}Co source). Band represents CSF-cutaneous fistula.

trauma. The spleen is ruptured or lacerated twice as often as the liver in blunt abdominal trauma. The mortality of liver damage is higher than that of the spleen, accounting for as many as 30% of the deaths occurring after closed abdominal injury.

Clinical and laboratory data are often non-specific, as are plain films of the abdomen. Radionuclide imaging is as reliable as angiography (see below) and does not require arterial puncture or injection of large doses of hyperosmotic media.

Examination is performed within a few minutes after injection of 1 to 3 millicuries of $^{99\text{m}}\text{Tc}$ -sulfur colloid. Anterior, posterior, and lateral views are absolutely necessary. Oblique and angled views are often needed for full evaluation of the spleen (see below). Some investigators have found dynamic imaging useful, but its role is less vital than in skull, renal, and vascular injury.

Laceration of a solid organ causes a linear or focal defect in the visualized activity (Figs 4, 5). A localized hematoma causes a round or wedge-shaped

defect that, on appearance alone, can be indistinguishable from tumor, abscess, cyst, or infarct. A bipartite or accessory spleen may simulate transection, but this has not yet been a clinical problem in our experience. Subcapsular hematoma causes a flattening of the border of the liver or spleen, and separation of the organ from the body wall or diaphragm, but the latter is difficult to discern on radionuclide imaging, and variations in normal organ position can be deceptive. Patchy or inhomogeneous uptake may also be seen and, in the liver, must be differentiated from cirrhosis.

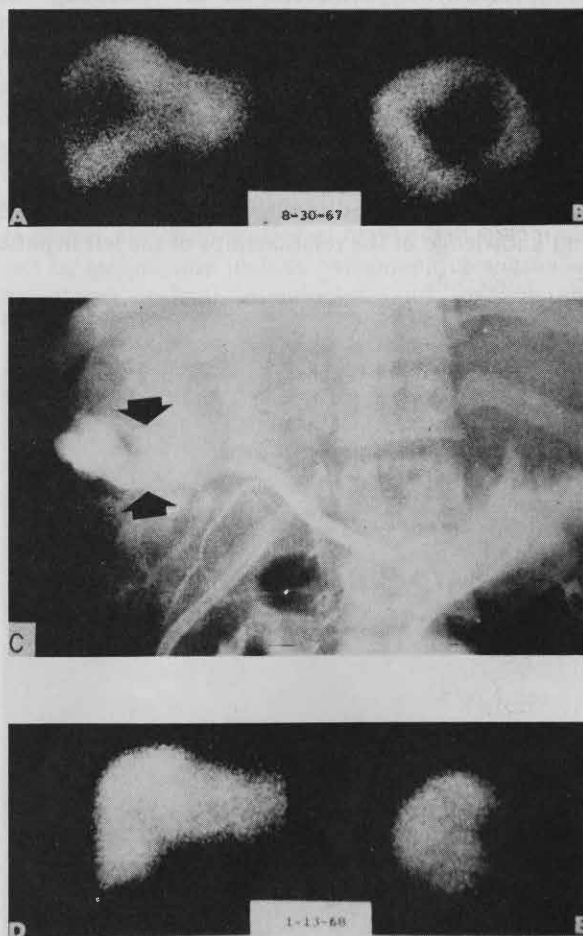


Fig 4—Liver laceration and hematoma in young male adult after motorcycle accident. *A* and *B* are anterior and right lateral $^{99\text{m}}\text{Tc}$ -sulfur colloid liver scintiphotos, respectively, which show a large right lobe defect. In *C*, selective hepatic angiography shows pooling of opaque material in a large cavity (arrows) which corresponds to the defect seen on scan. This represents pseudoaneurysm with hematoma formation. *D* and *E* are scintiphotos obtained 5 months after surgical repair. The tremendous regenerative ability of hepatic tissue is demonstrated.

No false-negative results have been reported in diagnosing hepatic injury. The incidence of false-positive scans is quite low, on the order of 3% or less (Table 1). Because no clinically significant injury will apparently be missed, it is a suitable screening test for liver damage. Angiography can be reserved for equivocal cases or when precise anatomic definition is necessary for surgery.

Spleen imaging has led to a correct diagnosis in about 90% of more than 200 cases reviewed (Table 2). In terms of clinically significant splenic damage, the accuracy of the procedure is even higher. Intraparenchymal extravasation or "puddling" as seen on angiography is not a criterion for surgery if it is the only demonstrable abnormality; such a case accounts for one of the so-called "false-negative" cases reported. A proven subcapsular hematoma has been missed scintigraphically, since the expected flattening of the splenic border was not present.

Attention to positioning of the detector head and knowledge of the relationships of the left hepatic

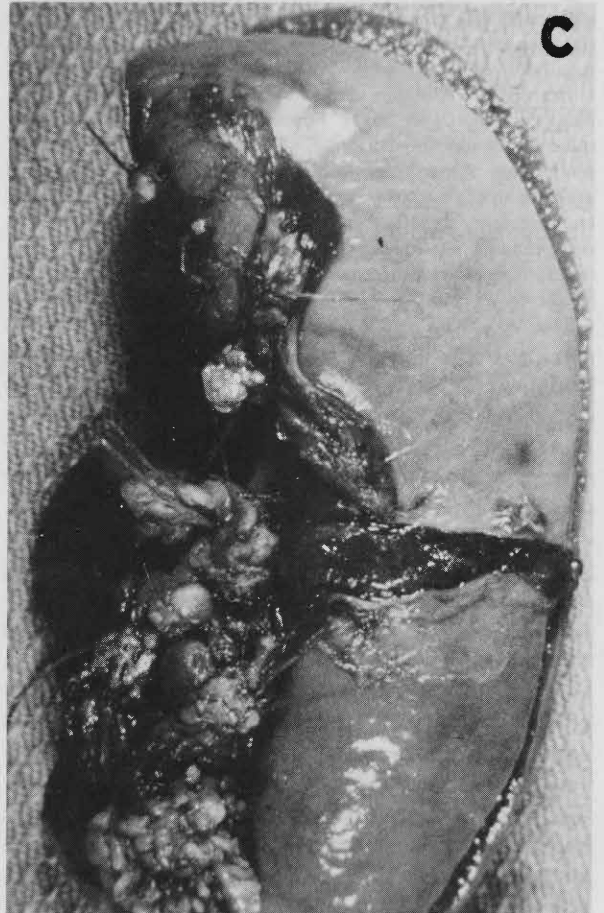
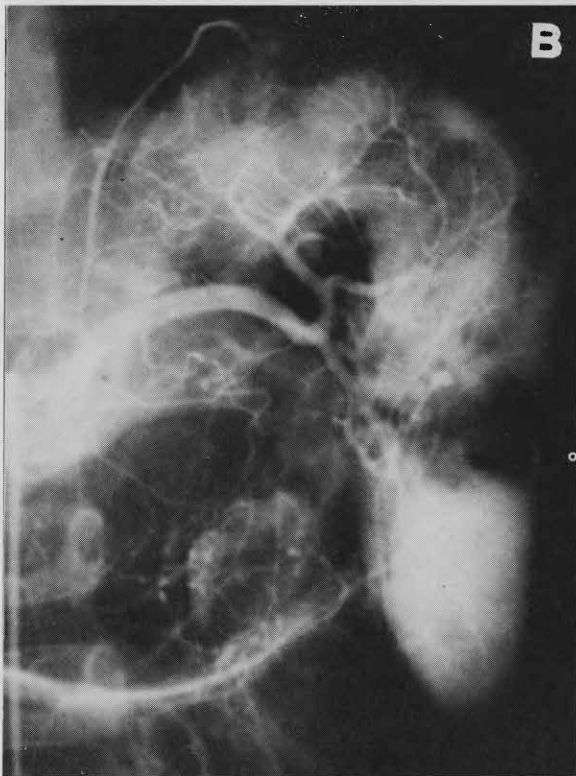
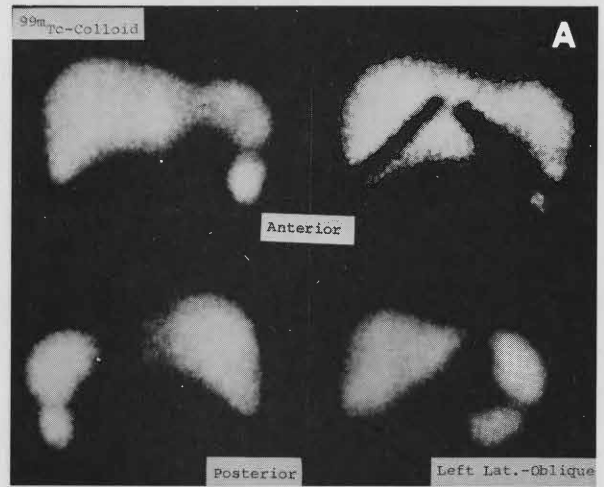


Fig 5—Ruptured spleen in a 9-year-old boy after trauma. *A.* ^{99m}Tc -sulfur colloid scintiphotos show a large spleen with a wide lucent band through the midportion. *B.* Selective celiac angiogram also shows the wide defect seen in the splenogram. *C.* Longitudinally cut surgical specimen confirms the rupture through the midbody of the spleen.

TABLE 1
Liver Imaging in Abdominal Trauma

| Study | No. of Patients | True Negative | False Negative | True Positive | False Positive | % Correct |
|-------|-----------------|---------------|----------------|---------------|----------------|-----------|
| A | 119 | 100 | 0 | 17 | 2 | 98.3 |
| B | 19 | 16 | 0 | 3 | 0 | 100 |
| C | 8 | 3 | 0 | 5 | 0 | 100 |
| D | 16 | 15 | 0 | 1 | 0 | 100 |
| | 162 | 134 | 0 | 26 | 2 | 98.7 |

lobe to the spleen can minimize the chance of false-positive diagnosis of spleen injury. Angling and obliquing the detector allows visual separation of the spleen from the overlapping left hepatic lobe, which, in the straight posterior position, may simulate a wedge-shaped defect in the spleen (see accompanying article on pitfalls and artifacts in this issue). Rib impressions may also simulate lacerations, but can be suspected by the orientation of the defect and ruled out by obtaining views with a lead strip marker in place over the rib.

With an unequivocally normal study, further examination of the spleen and liver is usually unnecessary. A critically ill patient with a definitely abnormal scan requires surgery. In cases of equivocal imaging findings or atypical history or physical examination, angiography may be necessary for further evaluation. This is particularly important when there is a possibility of subcapsular hematoma, which can lead to delayed rupture. However, despite the superior resolution of angiography, sizable lesions may be missed, possibly because it is difficult to obtain multiple projections (Fig 6).

Any patient with trauma to the left upper quadrant should be evaluated for possible kidney injury in addition to splenic injury.

III. Genitourinary Tract Injury.

Although penetrating wounds and iatrogenic damage such as renal biopsy and surgery account for a number of renal injuries, about 90% are the result of blunt abdominal trauma, predominantly automobile accidents. Severe renal injury is not so often an immediate threat to life, as is severe hepatic or splenic injury, except in cases of penetrating injury. However, the late sequelae of renal parenchymal loss can be serious and include hydronephrosis, calcified hematoma, calculi, pseudocyst, and scarring and arterial injury leading to hypertension.

Minor renal damage occurs in the majority (65%) of instances of renal injury, according to the widely used classification of Hodges, et al. Contusion is the commonest minor injury. Major disruption of the parenchyma, with rupture of the capsule, extension into the collecting system, and/or segmental vascular occlusion accounts for 30% of renal injuries. Critical injury, with disruption of the renal hilus with its major vessels, is rare.

Although the intravenous urogram, preferably with a high dose of contrast media, is usually the first examination performed in the patient with suspected renal injury, studies of diagnostic quality cannot always be obtained. A rapidly running intravenous

TABLE 2
Spleen Imaging in Abdominal Trauma

| Study | No. of Patients | True Negative | False Negative | True Positive | False Positive | % Correct |
|-------|-----------------|---------------|----------------|---------------|----------------|-----------|
| A | 119 | 91 | 0 | 24 | 4 | 96.6 |
| B | 19 | 14 | 0 | 5 | 0 | 100 |
| C | 32 | 19 | 1 | 11 | 0 | 93.7 |
| D | 16 | 2 | 1 | 12 | 1 | 87.5* |
| E | 16 | 9 | 0 | 7 | 0 | 100 |
| | 202 | 135 | 2 | 59 | 5 | 96.0 |

* False-positive can be avoided. False-negative was insignificant puddling. (see text).

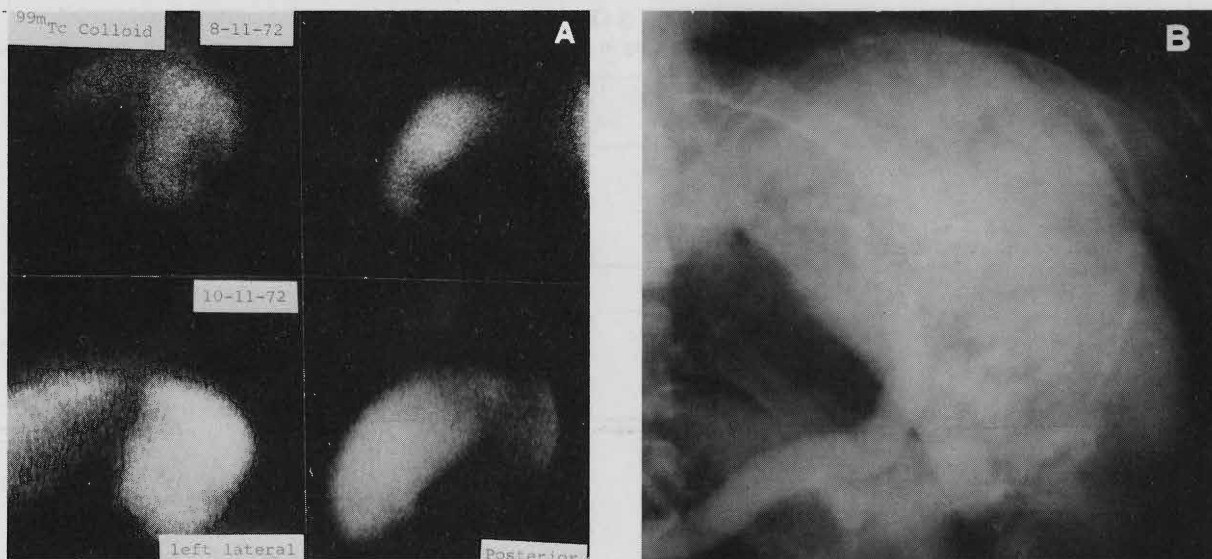


Fig 6—Minor nonsurgical spleen injury in 33-year-old man after stab wound. *A*. A ^{99m}Tc -colloid study at the time of injury (*top row*) shows a focal area of decreased uptake along the posteromedial border. Angiogram performed at this time is shown in *6B*. Repeat radionuclide study two months later (*bottom row*) in the same left lateral and posterior views show disappearance of the abnormality. *B*. Selective splenic angiogram (late phase) at time of injury in anteroposterior position fails to show the abnormality seen on the scintigraphic study. Apparent lucencies over the lower portion of the spleen represent bowel gas.

line can cause significant dilution of the contrast media, and overlying gas and feces can interfere with interpretation.

Radionuclide examination, in dynamic and static modes, provides information about the vascular supply of the kidney, parenchymal integrity, and excretory function, combining some aspects of both urography and angiography. For dynamic imaging, a 10 to 15 millicurie bolus of one of the ^{99m}Tc -labeled renal agents is injected rapidly into a peripheral vein, preferably the antecubital. Beginning 6 seconds after injection, 2- to 3-second exposures are obtained until approximately 30 seconds after injection. If rapidly filtered ^{99m}Tc -Sn-DTPA is used, immediate and serial scintiphotos over a 30-minute period are made. If one of the agents that is fixed to the tubules is used (^{99m}Tc -iron-ascorbate, ^{99m}Tc -glucoheptonate, or ^{99m}Tc -DMSA), one- and two-hour static delayed images are obtained. The ^{99m}Tc -labeled compounds have largely replaced ^{197}Hg -chlormerodrin as cortical imaging agents because of more favorable physical characteristics.

The posterior view is used for renal imaging. A diverging collimator is helpful for imaging large adult patients, in order to image both kidneys simultaneously in one field, but is not necessary in the

average adult or in children. Delayed imaging of the bladder is done in the anterior position.

The commonest renal injury, cortical contusion, may cause early diminished blood flow on dynamic imaging and persistent defect or sometimes generalized decreased activity on delayed imaging (Fig 7). A persistent focal defect is difficult or impossible to differentiate from infarct or hematoma. Infarct will remain as a defect on follow-up imaging, while contusion may resolve over two to four weeks (Fig 7). Hematoma may resolve or progress to infarct.

If no activity is seen to reach the kidney on dynamic and subsequent static imaging, renal arterial occlusion or other disruption of the renal hilus must be suspected. This is an indication for immediate surgical intervention to attempt salvage of renal function. Arteriovenous fistula caused by trauma or renal biopsy is apparent on dynamic imaging as an area of early intense activity and rapid washout.

A fragment of lacerated or fractured kidney may demonstrate diminished perfusion early and increased activity late, but the associated linear defect dividing the kidney into more than one fragment often distinguishes this pattern from contusion.

Extravasation of activity can be seen in

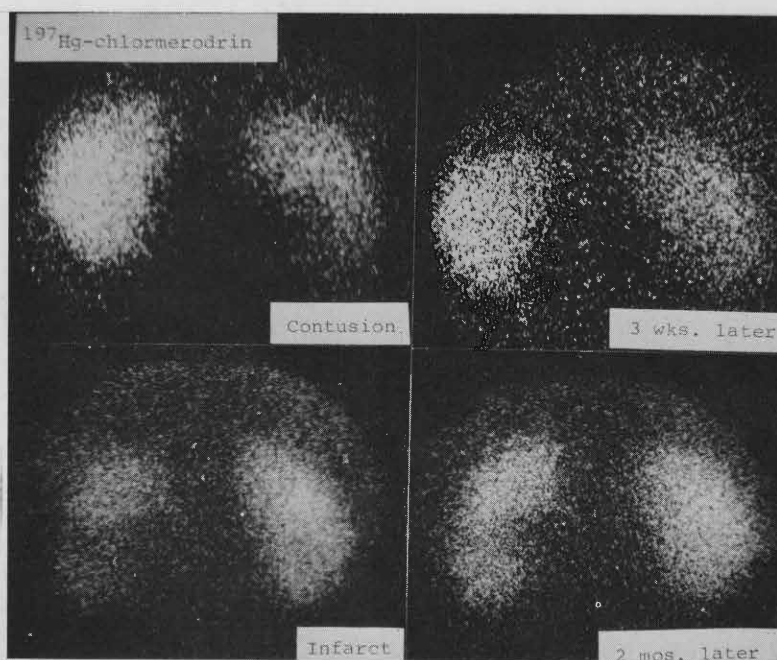


Fig 7—Value of serial radionuclide examination in differentiating between renal contusion and infarction. Posterior ^{197}Hg -chlormerodrin scintigraphy following blunt trauma (*top row*) shows diminished activity in the medial portion and lower half of the right kidney. Repeat study 3 weeks later demonstrates considerable improvement in the appearance of this contused kidney. Sequential radiochlormerodrin study in another patient with blunt trauma (*bottom row*) shows a band of decreased activity through the midportion of the left kidney, which remains relatively unchanged after 2 months. Subsequent studies showed no change over 4 additional months. An area of contused parenchyma seen below the infarct shows marked improvement on the 2-month study. This patient is being followed closely for the possible development of hypertension.

parenchymal and pelvocalyceal tears (Fig 8), and the chances of demonstrating it are increased if early and late scintiphotos are obtained. Extrarenal collections such as retroperitoneal hematoma, urinoma, and lymphocele (following renal transplant) cause voids in the visualized background activity and distort the urinary tract structures by their mass.

When total nonfunction of a kidney is seen on urography, and on dynamic and static renal imaging with a cortical agent, radiohippuran studies may be useful in determining the presence of functioning renal tissue. Hippuran I-131 is also useful in measuring renal function in cases where post-traumatic compromise is suspected and in following renal function in these cases.

Radionuclide examination compares favorably to angiography in detection and delineation of renal injury. It is reportedly superior to aortography in diagnosing mild to moderate renal injury such as contusion. Selective catheterization increases the diagnostic accuracy of contrast angiography, but also

increases the morbidity of the procedure. Radionuclide imaging often is superior to urography in defining the extent of damage, and sometimes demonstrates injury that would be unsuspected from urography alone. The development of ultrasonography provides a method to determine the presence or absence of a kidney that shows no function on urography. This noninvasive technique, with the virtually noninvasive radionuclide techniques described, can decrease the instances when angiography is required for renal evaluation after trauma.

IV. Peripheral Vascular Injury.

Dynamic imaging can be useful in evaluation of acute vascular injury and its sequelae. The basic principle, as with other dynamic imaging procedures described above, is rapid introduction of high-specific-activity radionuclide in a small volume (less than 1 ml). Usually $^{99\text{m}}\text{Tc}$ -pertechnetate is used. However, when it is desirable to obtain multiple views of an injured area, the first injection may be made with a substance which is removed by an organ

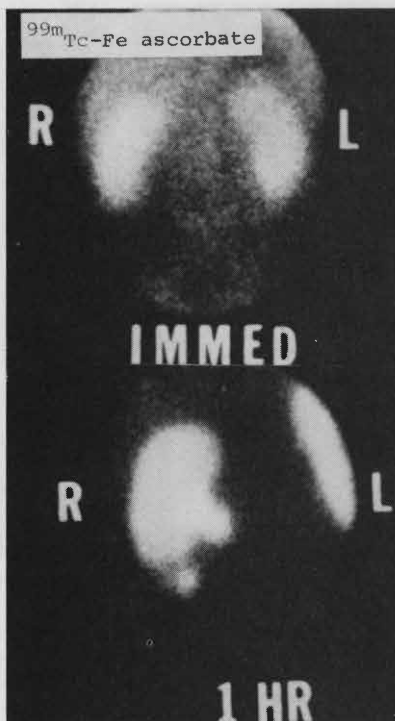


Fig 8—Renal laceration. Renal scintiphoto performed one minute after injection of ^{99m}Tc -iron-ascorbate shows a “cold” area at the lower pole of the right kidney. A follow-up study one hour later clearly shows the laceration at the lower tip of the kidney with activity leaking into the area of hematoma.

during one pass through the circulation, for example, ^{99m}Tc -S-colloid by the liver. The background radioactivity is then reduced, and the second injection can be made with pertechnetate. Scintiphotos are obtained every 2 to 3 seconds for 15 to 25 seconds, and a static image of 300,000 counts is obtained at conclusion of the dynamic phase. A data processor allowing subsequent playback and analysis can be helpful in this as in other dynamic examinations, but is not absolutely necessary for clinical usefulness.

Extravasation into a paravascular hematoma can be seen early as an irregular collection of activity adjacent to a vessel. The activity may increase in intensity in static images. A well-defined circular area of early increased activity in the vicinity of a major vessel suggests pseudoaneurysm, not an uncommon finding several weeks after trauma (Fig 9). Traumatic arteriovenous fistula, as described in the section on urinary tract injury, presents a picture of early activity in the fistula and draining vein, with early washout. Iatrogenic arteriovenous shunts for dialysis can be studied in the same way. Traumatic

occlusion of an artery will cause deficient activity in the area of its supply.

The venous system can also be visualized, if injection is made into the vein distal to the site of injury. Technetium- ^{99m}Tc -MAA or microspheres are used for venous studies. Collateral circulation and actual sites of thrombosis or other occlusion can be demonstrated.

V. Skeletal Trauma.

The extensive use of radionuclide imaging in benign bone disease is a relatively new phenomenon, facilitated by the development of ^{99m}Tc -labeled phosphate complexes (polyphosphate, diphosphonate, and pyrophosphate). These compounds are relatively inexpensive, widely available, have convenient physical characteristics, and yield a low patient radiation dose, thus overcoming most of the objectionable qualities of previously used compounds. The body of literature on radionuclide imaging findings in trauma is small, much of the experience having been gained incidentally in study of malignant disease with ^{85}Sr , ^{87m}Sr , and ^{18}F .

With the ^{99m}Tc agents, bone imaging is performed two to four hours after intravenous administration of 10 millicuries of the phosphate complex in adults, or appropriately smaller doses in children. Total body scanning with a high-speed, dual-probe scanner or camera with moving table or detector accessories is desirable for potentially generalized problems. Localized studies are usually performed on the gamma camera, which yields high-resolution images with these compounds.

A useful area of examination in acute trauma is in detection of a bone bruise or fracture that may be difficult to detect radiographically, such as in the ribs, or in the vertebral column (Fig 10). In children, fractures may be difficult to detect because of incomplete ossification of the skeleton. Such sites of trauma can be appreciated on imaging studies, which depend on the hyperemia associated with reaction to trauma, rather than on mineral density of the bone. The pattern of injury in the appropriate context may suggest child abuse at a time when radiography is equivocal.

After two to three days, both actual fractures and periosteal or superficial bone injury without fracture may be “hot” despite negative radiographs (Fig 10). The activity decreases in intensity over a period of several months to years. The pattern of activity involving multiple bones can help distinguish trauma from osteomyelitis, which also can cause intensely “hot” uptake, but is not commonly multifocal.

Imaging is particularly valuable in following the

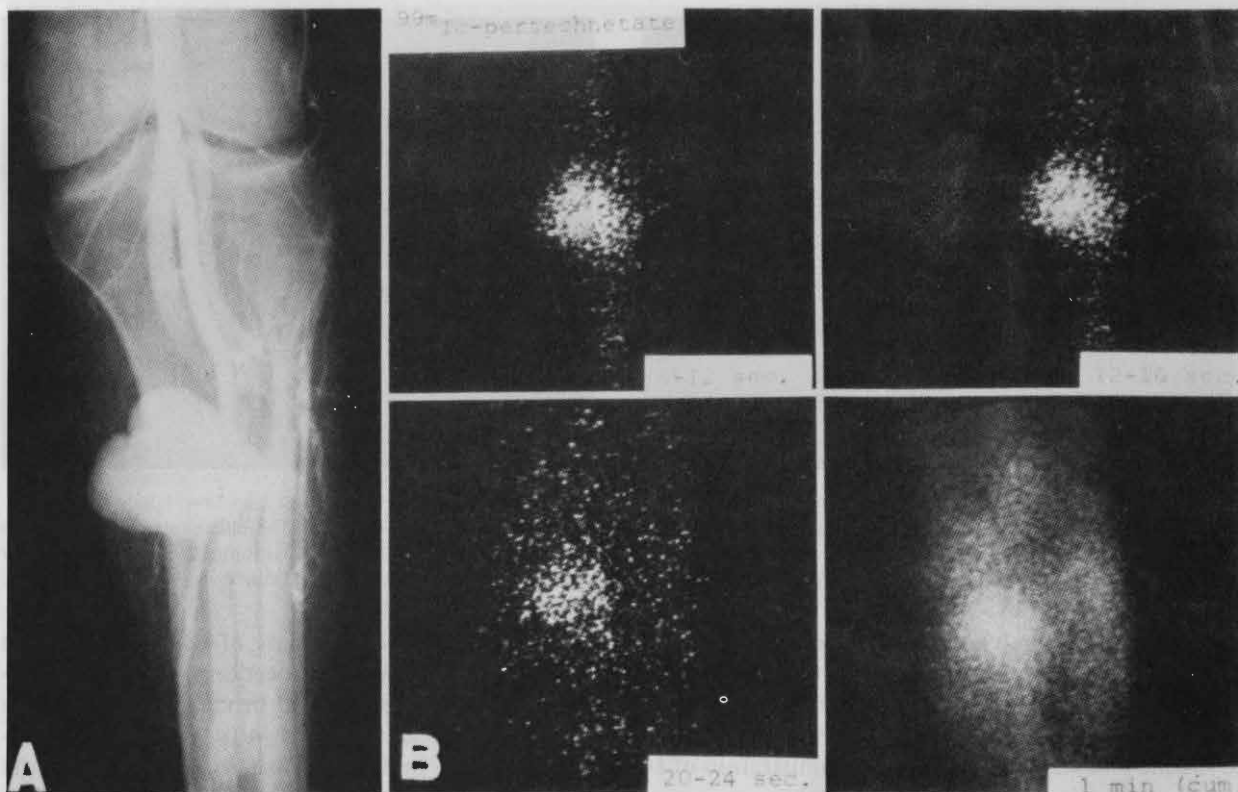


Fig 9—Pseudoaneurysm of left peroneal artery after stab wound. *A*. Angiogram demonstrates the presence of a large pseudoaneurysm with arteriovenous shunting in the distribution of the left peroneal artery. *B*. Serial scintiphotos performed over the knee area following a bolus injection of ^{99m}Tc -pertechnetate reveal a large collection of activity which remains long after the vessels empty. A one-minute static cumulative image shown at the lower right contrasts with the background vascular activity in the muscle mass of the leg.

healing process after accidental fracture or iatrogenic trauma such as osteotomy or bone graft. Activity bridging the gap in the bone will appear before radiographically visible bony bridging. Failure of this to occur predicts nonunion or pseudarthrosis formation.

The possibility of aseptic necrosis of the femoral head following subcapital fracture may be accurately predicted by demonstrating diminished activity early, with failure of activity to return after several weeks. Revascularization of an area of aseptic necrosis causes increased activity (11).

Artifacts of increased activity may be seen in soft tissue injury such as incisions or organizing hematomas, as well as in ectopic bone formation, following trauma and other insults. It is common to see diffusely increased activity over the upper hemithorax after mastectomy. Although this may be partly due to decreased photon attenuation by the smaller mass of overlying soft tissue, the absence of improved rib definition suggests that it is actually soft tissue activity. It must be differentiated from tumor recurrence,

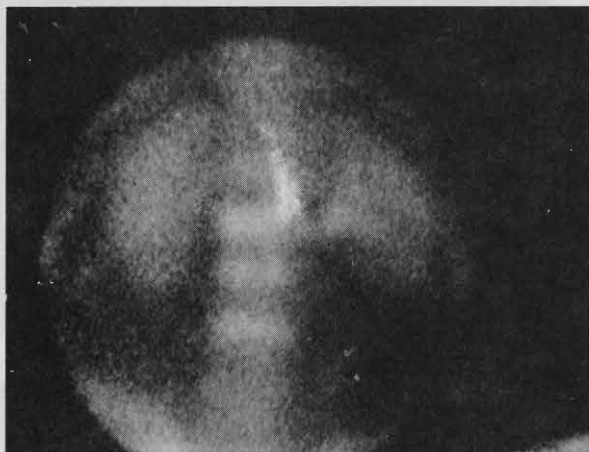which can cause localized increased activity, and from malignant pleural effusion. The latter is generally more diffuse and is present on both posterior and anterior views.

Radiation injury to the bone, as to other organs, ultimately causes a sharply defined field of diminished uptake, although in the early post-irradiation period, activity may be greater than normal.

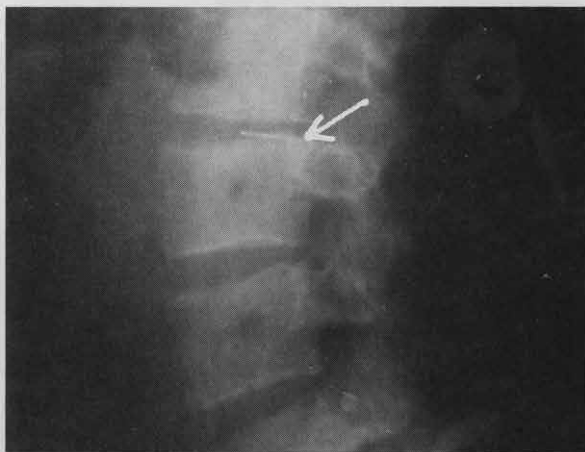The ^{99m}Tc -phosphates are excreted by the kidney. Therefore, urine contamination must be avoided, especially in bone imaging of the pelvis and lower extremities, where it is likely to occur in the severely ill patient. The bladder should be empty in pelvic studies to avoid obscuring information.

VI. Chest Injury.

The methods of evaluating vascular and bone injury have already been described. Imaging has been used in evaluation of hemothorax and pulmonary contusion, but these studies do not actually add to the diagnostic capabilities of conventional radiography.



A.



B.

Fig 10—Multiple spinal fractures seen on scintiphoto with only one fracture demonstrable on x-ray. The patient was a fireman who leaped out of a window landing on his feet. A. Posterior ^{99m}Tc -pyrophosphate bone scintiphoto 4 days after injury shows 4 active lumbar vertebral bodies. B. Lateral lumbar spine x-ray shows disruption of L3 superior vertebral plate (arrow). Multiple views failed to show any other evidence of fracture.

Traumatic hemopericardium, like other pericardial fluid collections, can be diagnosed by demonstrating a clear “halo” around the heart, separating it from lung and liver activity, during dynamic and static studies after administration of 10 to 15 millicuries of ^{99m}Tc -pertechnetate.

Fat embolism and “shock lung” cause multiple perfusion defects or diffuse inhomogeneity of activity on routine lung imaging with ^{99m}Tc -labeled macroaggregates of albumin or microspheres. Although the imaging findings are indistinguishable from pulmonary emboli of other etiologies, in the appropriate clinical setting the study may confirm the diagnosis.

Inhalation studies with ^{133}Xe may help to diagnose burns of the respiratory tract. Areas of delayed filling and slow washout suggest obstruction to air flow. This may be seen in chronic obstructive lung disease, foreign body, or bronchiectasis, but in the appropriate setting can confirm a suspicion of tracheobronchial injury or edema related to smoke or fume inhalation. If ^{133}Xe in saline is injected intravenously, perfusion defects can be documented, and subsequent rebreathing permits evaluation of ventilation patterns.

Conclusion. Radionuclide imaging provides useful functional and anatomic information about many organ systems, especially when dynamic and static phases are utilized. In any but the most acute patient in need of immediate lifesaving therapy and direct surgical intervention, these studies might well

be considered a routine part of the evaluation. In many cases, invasive procedures such as angiography, myelography, and bronchography may be avoided, or at least limited in time and extent. Acceptably low radiation doses make multiple and follow-up studies reasonable.

By facilitating early treatment of traumatic injury in many cases, and by eliminating expensive and complicated procedures in others, the more widespread utilization of these techniques can help to decrease the tremendous human and economic costs of trauma.

Table 1 and Table 2 are adapted from Gilday and Alderson, *Seminars in Nuclear Medicine* (4:357-370, 1974).

Figures 3 and 4 are reprinted from the *Journal of Nuclear Medicine*, Vol. 14, No. 6, and Vol. 10, No. 10, respectively, with permission of publisher.

Figures 5 and 6 are reprinted from *Radiology* (110:419-425, 1974) with permission of authors and publisher.

Figures 7 and 8 are reprinted from *Seminars in Nuclear Medicine* (4:117-132, 1974; 4:371-393, 1974, respectively) by permission of Grune & Stratton.

Figure 9 is reprinted from *Radiology* (109:623-628, 1973) with permission of authors and publisher.

REFERENCES

(Review Articles 1 through 4)

1. Radionuclide studies in evaluation of trauma. *Semin Nucl Med* Vol. 4, October 1974.
2. TSAI SH: Techniques of nuclear medicine in the diagnosis of trauma. *CRC Crit Rev Clin Radiol Nucl Med* 5:495-522, 1974.

3. FREEDMAN GS: Radionuclide imaging of the injured patient. *Radiology Clin North Am* 11:461-477, 1973.
4. KOENIGSBERG M, BLAUFOX MD, FREEMAN LM: Traumatic injuries of the renal vasculature and parenchyma. *Semin Nucl Med* 4:117-132, 1974.
5. BELL RS, LOOP JW: The utility and futility of radiographic skull examination for trauma. *New Eng J Med* 284:236-239, 1971.
6. ROBERTS F, SHOPFNER CE: Plain skull roentgenograms in children with head trauma. *Am J Roentgenol Radium Ther Nucl Med* 114:230-240, 1972.
7. HOLMES RA, ISITMAN AT: ^{99m}Tc DPHA: The Optimum Radiopharmaceutical for Brain Imaging. Presented at the 22nd Annual Meeting of The Society of Nuclear Medicine, Philadelphia, June 1975.
8. WAXMAN AD, TANASESCU JK, SIEMSEN JK, ET AL: ^{99m}Tc -glucoheptonate as a Brain Scanning Agent: A Critical Comparison with Per technetate. Presented at the 22nd Annual Meeting of The Society of Nuclear Medicine, Philadelphia, June 1975.
9. ECTORS M, ABRAMOVICI J, JONCKLEER MH: Comparative Study of ^{99m}Tc -citrate, ^{99m}Tc -diphosphonate, and ^{99m}Tc -per technetate in Brain Scintigraphy. Presented at the 22nd Annual Meeting of The Society of Nuclear Medicine, Philadelphia, June 1975.
10. LIEBESKIND AL, HERZ DA, ROSENTHAL AD, ET AL: Radionuclide demonstration of spinal dural leaks. *J Nucl Med* 14(pt 1):356-358, 1973.
11. STADALNIK RC, RIGGINS RS, D'AMBROSIA R, ET AL: Vascularity of the femoral head: ^{18}F fluorine scintigraphy validated with tetracycline labeling. *Radiology* 114:663-666, 1975.

Radioimmunologic Methods for Diagnosis of Malignant Diseases

PAUL B. HOFFER, M.D.

Professor of Radiology and Director, Section of Nuclear Medicine, University of California Medical Center, San Francisco, California

The recent availability of the carcinoembryonic antigen (CEA) assay has stimulated great clinical interest in tumor antigens. Carcinoembryonic antigen is not the only specific or tumor-associated antigen currently identified. There are a number of other tumor antigens which have been isolated, some of which are related to CEA and some of which are totally different. There is, for example, a nonspecific cross-reacting antigen (NCA) which has been discovered in certain preparations which were considered originally to be CEA. Nonspecific cross-reacting antigen is a beta globulin (25% carbohydrate) which cross-reacts with antibodies to CEA and may be the nonspecific background element that causes the CEA titer to be elevated in certain nonmalignant diseases. There is also a membrane-associated, low molecular weight tissular autoantigen (MTA) which has been recently identified. However, this material is not antigenetically related to CEA or NCA.

Carcinoembryonic antigen is an antigenetic glycoprotein. The antibody-active site of this antigen is actually in the glucose portion of the molecule rather than the protein portion. Carcinoembryonic antigen has a relatively high molecular weight (200,000) and is soluble in perchloric acid. The perchloric acid solubility of CEA has greatly facilitated extraction of the antigen from tumor tissue and is also responsible for the relative convenience of the current method of performing the radioimmunoassay for detection of this antigen.

Carcinoembryonic antigen is present in the

glycocalyx of malignant gastrointestinal cells and is also present in fetal gastrointestinal tissues during the first and second trimesters of fetal life. Gold and Freedman discovered and isolated this material in 1965 (1). A radioimmunoassay for its detection was developed soon after (2). Initial results with this assay indicated that elevated blood CEA level was a specific test for adenocarcinoma of the colon, although occasional patients with pancreatic carcinoma also had elevated titers. However, more extensive clinical studies indicate that circulating CEA is not only present in colonic and pancreatic malignancies but in other malignancies as well, as noted by H. J. Hansen, MD (oral communication, April, 1973). Unfortunately, CEA is also present in certain nonmalignant disorders and some normal patients. The common denominator in most cases of elevated CEA level associated with bowel disease is rapid cellular proliferation with disruption of the basement membrane. The disruption of the basement membrane is important because the antigen must leak into the circulation in order to be detected. The cellular proliferation may be responsible for the cell surface exposure of certain primitive antigens that are not normally found in adult human tissues. The upper limit of normal for the currently available CEA assay is approximately 2.5 ng/ml. However, a finite percentage of normal individuals will have CEA levels above this value. Three percent of healthy, young nonsmoking volunteers and 19% of smokers have CEA levels over 2.5 ng/ml. There is some question as to whether the smokers who do have elevated titers are not in fact candidates for developing carcinoma of the lung, although the evidence for this is currently speculative. Former smokers have a fairly significant CEA titer

This is an edited transcription of a lecture presented by Dr. Hoffer at the Postgraduate Course in Nuclear Medicine, February 27, 1975, in Williamsburg, Virginia.

elevation. Thirty percent of patients with nonmalignant disease may have a titer above 2.5 ng/ml, and 10% of these patients have a titer above 5 ng/ml. However, the assay shows more frequent and more marked elevation of the antigen titer in patients with malignancy, especially colorectal carcinomas. Eighty percent of patients with colorectal carcinoma have a titer greater than 2.5 ng/ml. Fifty percent have a titer above 5 ng/ml. Other tumors such as lung carcinoma are also associated with a high incidence of elevated titer.

An early criticism of the CEA assay was the high incidence of false-negative results in patients with early-stage colonic carcinomas. The five-year survival statistics for treated patients with Duke's stage A colonic carcinoma is almost 100%. In the stage B group, the survival is approximately 50% to 60%, and in the stage C group (those patients in whom the tumor has gone through the serosa and actually metastasized to local nodes), the survival drops to only about 25% at five years. Ideally, we would prefer an assay that would detect 100% of patients with colonic carcinoma, Duke's stage A (assuming that most of these tumors do go through a progression from stages A to C). However, using the current CEA assay, only 20% of patients with stage A lesions will have an elevated titer. In other words, 80% of the patients with this type of lesion will have a normal CEA titer. About 40% to 50% of patients with stage B lesions will have positive titers. It is only when the lesion actually breaks through the serosa and is involving local nodes that the probability of an elevated CEA titer approaches 90% to 100%. Therefore, the current CEA immunoassay cannot be used alone as a cancer-screening study. Its value in screening patients, however, should not be totally discounted since there is a significant five-year survival in treated patients even in the stage B and C categories.

Doctor William McCartney, Mrs. Erika Lawrence, and I performed a study at the University of Chicago, comparing the relative value of the CEA titer to the conventional colon examination for the diagnosis of carcinoma of the colon (3). The study included almost 1,000 patients who were referred for radiologic colon examination. Carcinoembryonic antigen titer above 3 ng/ml (a level we arbitrarily selected to divide the normal from abnormal groups) was detected in 15% of patients subsequently diagnosed as normal, or having inactive inflammatory bowel disease. There was a 30% incidence of elevated titers in patients who had cirrhosis and noncolonic malignancies. Less than

10% of the patients with benign colonic polyps in this series had significant titer elevation.

By comparison, the conventional radiologic colon examination was positive, that is, showed evidence for malignancy in only 10 out of 850 patients who were subsequently established not to have colonic malignancy. The colon examination was, therefore, much more specific for excluding the diagnosis of carcinoma of the colon in patients subsequently proven not to have colonic malignancy.

Forty-eight of the patients in this series were subsequently proven to have carcinoma of the colon, first diagnosed at the time of the study. The CEA titer was normal in 16 of these patients and was abnormal in only 67%, whereas the conventional radiologic colon examination was abnormal in 90% of these patients. The radiologic colon examination was, therefore, clearly superior to the CEA test for detection of new carcinomas of the colon. However, there were three patients with carcinoma of the colon in this study in whom the radiologic colon examination was originally considered to be normal or show signs representing benign disease, who did have elevated CEA titers. The CEA titer was potentially helpful in these cases in raising the suspicion of colonic carcinoma. If the results of the two tests are combined, the accuracy of the diagnosis is 96%, which represents some improvement over the radiologic colon examination alone.

In active ulcerative colitis, the CEA level is frequently elevated and the level itself is not a useful clue to detect early development of malignancy. The patients with quiescent bowel disease usually have normal titers. In a patient with quiescent bowel disease, a rising CEA titer should be treated with great suspicion for neoplasm.

Although the radiologic colon examination is clearly superior for the initial diagnosis of colonic malignancy, the CEA titer is equally superior for the diagnosis of recurrence of colonic carcinoma. In our studies of patients with recurrent colonic carcinoma, only 2 of 15 patients with recurrence had a normal CEA titer. The barium enema indicated recurrence in only 3 of these 15 patients. The barium enema did detect the two cases of recurrence with normal CEA titers. Frequently, the recurrence of colonic carcinoma is not in the area of the primary tumor but rather in the liver or elsewhere in the body. It is also very difficult to distinguish postoperative changes in the bowel from early recurrence of tumor on a conventional radiologic colon examination. These factors probably account for the poor detection rate of

recurrence seen with the conventional radiologic colon examination.

In summary, the CEA titer is not as sensitive as the radiologic colon examination for the diagnosis of primary carcinoma, but it is very useful in following patients for recurrent carcinoma.

Another area of potential use for the CEA radioimmunoassay is in the detection of metastatic malignancy of noncolonic origin. The test is extremely useful when interpreted in conjunction with other tests for metastatic disease. Doctor William McCartney, Erika Lawrence, and I studied 368 patients who had both liver scans and CEA immunoassay (4). The liver scan is a useful test for the detection of hepatic metastasis for many primary malignancies; however, it has a 30% incidence of false-negative results and a 10% to 20% incidence of false-positive results. The false-positive cases are primarily patients with other disorders such as cirrhosis, who show lesions on the liver scan which closely mimic metastatic tumor. In this study, we chose a level of 9 ng/ml as a dividing line between a positive result for metastatic tumor and negative evidence for metastatic tumor. It should be noted that this level is considerably higher than the level usually selected for detecting carcinoma of the colon.

Neither the liver scan nor the CEA assay was perfect in detecting hepatic metastasis. However, when the results of both tests were positive, the probability that the patient had metastasis was almost 100%, and when both tests were negative, the probability of hepatic metastasis dropped to 1%. If the liver scan only was positive, the probability of metastasis dropped to 60%, and if the CEA titer only

was positive, that is, above 9 ng/ml, the probability of hepatic metastasis was only 30%. These results suggest an important role of the CEA titer in evaluating the patients with many types of tumors other than colonic malignancy.

The continuing clinical use of the CEA titer will undoubtedly reveal many other situations in which the study is valuable. It is certainly not a diagnostic panacea, and the results must be interpreted with considerable caution. However, I believe we can look forward to an era of continued expansion in this type of tumor radioimmunoassay. More specific assays for colonic tumor are being developed and will undoubtedly become available in the future. I am equally confident that similar assay techniques will be developed for other types of malignancies.

REFERENCES

1. GOLD P, FREEDMAN SO: Demonstration of tumor-specific antigens in human colonic carcinomata by immunological tolerance and absorption techniques. *J Exp Med* 121(pt 1): 439-462, 1965.
2. THOMAS DMP, KRUPPEY J, FREEDMAN SO, ET AL: The radioimmunoassay of circulating carcinoembryonic antigen of the human digestive system. *Proc Natl Acad Sci USA* 64:161-167, 1969.
3. MCCARTNEY, WH, HOFFER PB: The value of carcinoembryonic antigen (cea) as an adjunct to the radiological colon examination in the diagnosis of malignancy. *Radiology* 110:325-328, 1974.
4. MCCARTNEY WH, HOFFER PB, LAWRENCE E: Use of the cea titer as an adjunct to the liver scan in the diagnosis of hepatic metastases. *J Nucl Med* 15(pt 1):514-515, 1974.

Pitfalls and Artifacts in Nuclear Imaging Studies

LEONARD M. FREEMAN, M.D.

Associate Professor of Radiology and Co-director of the Division of Nuclear Medicine, Albert Einstein College of Medicine, Bronx, New York

In interpreting scintillation images, one often is confronted with a variety of deviations from the typically normal study that need not represent definite pathology. Apart from normal anatomic variants in the position, shape, or configuration of an organ, one must also be prepared to appreciate alterations due to the radiodiagnostic agent employed and aberrations caused by faulty or improperly used instruments. Additionally, physiologic and/or functional changes associated with specific organ studies have provided a major source of error in routine image interpretation. It is the purpose of this article to acquaint (or reacquaint, as the case may be) the reader with many of these problems so that they may easily recognize them and, one hopes, improve their overall interpretive abilities.

The discussion will follow the lines of general considerations relating to instrumentation and radiopharmaceuticals followed by specific organ considerations. In this type of review, some intentional as well as some unintentional omissions may appear. The author hopes that most of the common sources of error have been included. Undoubtedly, some readers may think of other problems that they may personally have been confronted with.

I. Instrumentation. Problems related to instrumentation may be related to malfunction of the equipment or faulty technique.

A. Malfunction:

1. *Lack of field uniformity.* In using scintillation cameras, one must have a relatively homogeneous response to gamma photons over the

entire crystal surface. A uniform crystal with properly balanced, normally functioning phototubes is a prime requisite to proper image interpretation. The response from different portions of the same crystal may vary from one another by as much as 20% to 30%. Computer programs have been written to correct this problem. Since most individuals do not have this facility, a simple field flood each morning using a sheet source or separate Cobalt-57 sources, with the collimator off, should, at least, help one appreciate what portions of the camera crystal are giving an inhomogeneous response. If the picture is particularly poor, the instrument should not be used and the manufacturer's service department should be consulted.

2. *Faulty spectrometer.* An inability to properly peak over the appropriate gamma photons of a radionuclide is a flaw that obviously would prevent one from obtaining a good image. Using the spectral bands available on the Anger scintillation camera, one should be able to appropriately "peak in" on the desired energy range. Using rectilinear scanners, one should be able to obtain maximal count response if the pulse height analyzer window is properly positioned around the peak gamma photon energy.

3. *Defects in the electronic circuitry (pre-amplifier, and other equipment) or display system (cathode ray tube, and other equipment).*

B. Technique:

Certain human errors also must be considered in operating any electronic instrument.

1. *Improper calibration.* Even though an instrument may be functionally sound, electronic "drifts" due to fluctuations in input voltage and other similar factors may cause changes in the settings required to obtain optimal response at a particular energy

From the Division of Nuclear Medicine, Department of Radiology, Albert Einstein College of Medicine, Bronx, New York, and presented by Dr. Freeman at the Postgraduate Course on Nuclear Medicine, February 28, 1975, Williamsburg, Virginia.

range. Frequent calibration checks by the technologist are needed to correct this difficulty.

2. *Faulty settings for contrast enhancement, density, or time contrast.* These are problems more often associated with rectilinear scanners than stationary cameras primarily related to the fact that there are many more dials for the technologist to manipulate on the former. Contrast enhancement settings deal with the range of gray scale over which the counts from the area being studied are spread. Too narrow a range will create a very contrasted image which may give a false impression of an abnormal area. The experienced interpreter should recognize this immediately. On the other hand, too little contrast enhancement may, in some instances, mask abnormalities. Similar situations may exist for density settings which deal with duration of light flash and time constant settings which deal with length of sampling time for a particular event or position of the detector.

3. *Information (count) density.* This refers to the amount of information one obtains in a unit area to create an interpretable rectilinear scan image. Nowadays, we strive for count densities of 600 to 2000 counts per square centimeter. A simple formula used to achieve this factor is as follows:

$$\text{Count Density} = \frac{\text{Maximal Count Rate}}{\text{Scan speed} \times \text{Line spacing}}$$

If one keeps the line spacing constant at 0.3 to 0.4 cm, a simple direct relationship between count rate and usable speed is obtained. A simple technique chart can be developed for the instrument operator relating these factors to obtain a desired count density.

4. *Improper collimator.* The use of an improper collimator can destroy an otherwise good study; for example, a low energy 140 kev collimator cannot be used for an ^{131}I -Hippuran renal study since the 364 kev gamma photon of ^{131}I will penetrate the collimator's lead septa causing considerable scatter radiation resulting in loss of resolution and image degradation.

Most of these aforementioned problems as well as several others are discussed at some length in a recent article by Harris (1).

II. Radiopharmaceuticals. Potential problems with radiodiagnostic agents are encountered in each individual organ-imaging area, and specific situations will be primarily considered as each organ system is discussed. These difficulties relate to both the preparation of these different materials as well as cer-

tain technical factors. Some general problems such as low specific activity or concentration, poor compound labeling, presence of radionuclide impurities, infiltration of the injected dose, and miscalculation of the dose are applicable to all of the subsequently discussed clinical areas.

III. Brain Imaging. In brain scintigraphy, difficulties with both the radionuclide angiogram (dynamic study) and blood-brain barrier study (static study) may be encountered.

A. Radionuclide angiogram.

1. *Jugular-venous reflux.* A sudden Valsalva maneuver by the patient during a rapid intravenous bolus injection of a radiopharmaceutical can cause the tracer to reflux up the jugular vein instead of proceeding on its normal pathway to the heart (2). This is recognizable as a band of activity entering the head (sometimes into the transverse sinuses) well before normal circulation time would fill the carotid arterial tree (Fig 1). It should not be misinterpreted as asymmetric arterial flow. A second factor that may cause such venous reflux is venous obstruction in the upper thorax, for example, superior vena caval obstruction, in which case reflux up the jugular represents the path of least resistance.

2. Expected asymmetries in elderly patients. Fif-

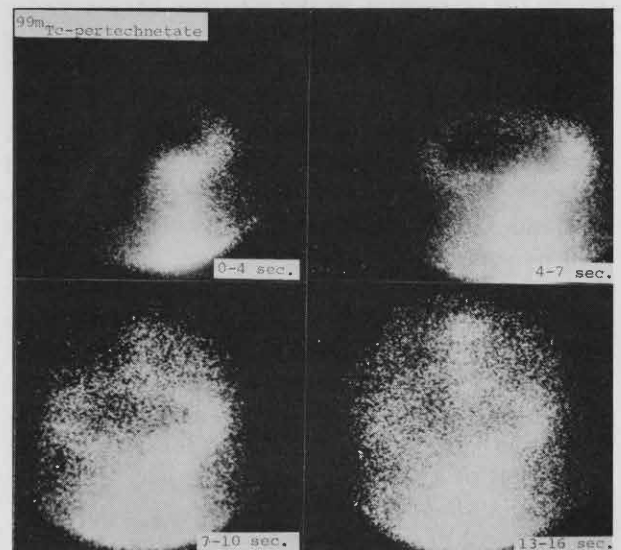


Fig 1—Jugulo-venous reflux. A bolus of $^{99\text{m}}\text{Tc}$ -pertechnetate administered through a left antecubital vein is seen to reflux up left jugular vein on 0-4-second scintiphoto. At 4-7 seconds, it has refluxed back into transverse sinus and down right jugular vein. At 7-10 seconds, normal arterial flow to head is visualized. Diminished right cerebral perfusion signifies presence of a right cerebrovascular accident.

teen to 20% of patients over the age of sixty can be expected to have asymmetric arterial flow solely on the basis of normal arteriosclerotic change (3). No focal neurologic findings are demonstrable in this group of patients.

3. *Bilateral carotid stenosis.* The author has encountered two situations where bilateral carotid artery stenosis has caused long delays in the cerebral appearance of an antecubital intravenous injection of ^{99m}Tc -pertechnetate. Since an infiltrated injection could cause the same finding, one should be aware of this particular disease entity when encountering such a study.

4. *Luxury perfusion in cerebrovascular accidents.* On occasion, increased rather than decreased flow may be observed in a patient with an acute cerebrovascular accident (3). This is believed due to regional hyperemia and vasodilatation around the infarcted area. This phenomenon generally subsides over a two- to four-week period. Such increased perfusion should not be misinterpreted as a vascular malformation or neoplasm.

B. Static brain studies:

1. *Choroid plexus activity.* The normal biologic localization of radiopertechnetate in the choroid plexus has been greatly emphasized (4, 5). Prior competitive blocking with potassium perchlorate has greatly minimized this problem. If continuing difficulty exists, even after perchlorate block, a repeat study with a different tracer such as ^{99m}Tc -DTPA may be obtained. The question of whether or not perchlorate premedication will prevent pertechnetate uptake in an abnormal choroid plexus, for example, papilloma or meningioma, has aroused some interest. In general, most reports indicate that it will not interfere with uptake in choroid plexus lesions. This was also the case in this author's large series of one case (Fig 2).

2. *Saliva artifacts.* Since pertechnetate is actively picked up by the salivary glands and excreted into the mouth, saliva artifacts must be watched for. This is generally encountered in comatose or semicomatose patients and children where drooling may allow saliva to collect on different parts of the head and neck (Fig 2). Repeat studies after cleansing of the area should resolve the problem.

3. *Prosthesis—metal plate, glass eye, and other artificial parts.* The relatively low gamma photon of ^{99m}Tc is easily attenuated by such foreign objects. The old standbys of physical examination and plain skull radiographs should clarify any suspicions in this area.

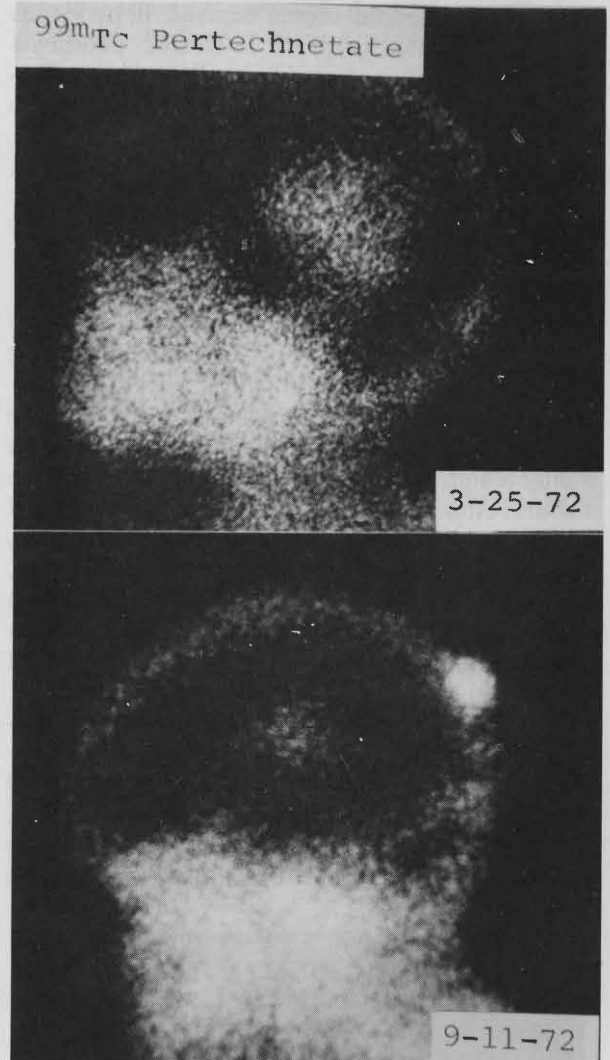


Fig 2—Uptake in choroid plexus papilloma in a child unaffected by potassium perchlorate premedication. Right lateral scintiphoto at top shows intense uptake in a choroid plexus papilloma. Pretreatment with perchlorate failed to block uptake in this abnormality. A follow-up study several months after radiotherapy is shown at bottom. The lesion has decreased in size. The "hot" spot on the back of the head is a salivary artifact caused by drooling.

4. *Superficial pathology.* The nonspecific uptake of radiopertechnetate includes lesions of the skull and scalp. Multiple views usually will clarify the problem since intracerebral abnormalities must be demonstrable on at least two images obtained at 90° angles. Extracerebral but intracranial abnormalities such as subdural hematomas, however, do not exhibit the finding and may be difficult to differentiate from more superficial pathology. Palpation of the scalp

and skull radiographs should be used. Bony lesions can be elucidated with ^{99m}Tc -labeled phosphate studies. In addition, serial studies with ^{99m}Tc -pertechnetate over a several-hour period may be useful, since most intracranial abnormalities show increased uptake with time, while most bone and soft tissue lesions seem to lose activity with time (6).

5. *Previous surgery.* Surgical flaps and other defects may concentrate a tracer and show activity for several years after an operation. It is useful to obtain a baseline study shortly after surgery. This makes judgments on subsequent studies concerning residual or recurrent abnormalities more lucid.

6. *Vertex view artifacts.* Mouth activity from the tongue and oral mucous membranes may mask a frontal lesion. Prior administration of atropine helps diminish this. Obvious attention to this use of atropine in problems of the elderly, for example, glaucoma and urinary retention, should be given. Visualization of the stomach on the vertex view in a child has been reported to cause some difficulty as well, since the appearance on that one view simulated a neoplasm.

7. *Need for serial studies after injection.* Considerable emphasis has been placed on the need to obtain delayed scintigrams in many intracranial problems, such as avascular primary neoplasms, metastatic lesions, and extracerebral hematomas. By confining the static brain scan to 45- or 60-minute

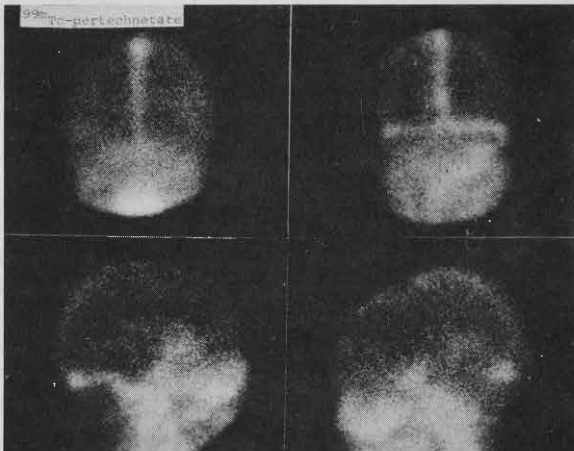


Fig 3—Abnormal ^{99m}Tc -pertechnetate brain image following a stannous pyrophosphate bone image. This 4-view static study 2 days after a pyrophosphate bone scan demonstrates increased activity in all vascular structures (sagittal sinus, transverse sinus, neck vessels, carotid siphon). The choroid plexus is particularly well seen on left lateral view despite perchlorate premedication (see text for explanation).

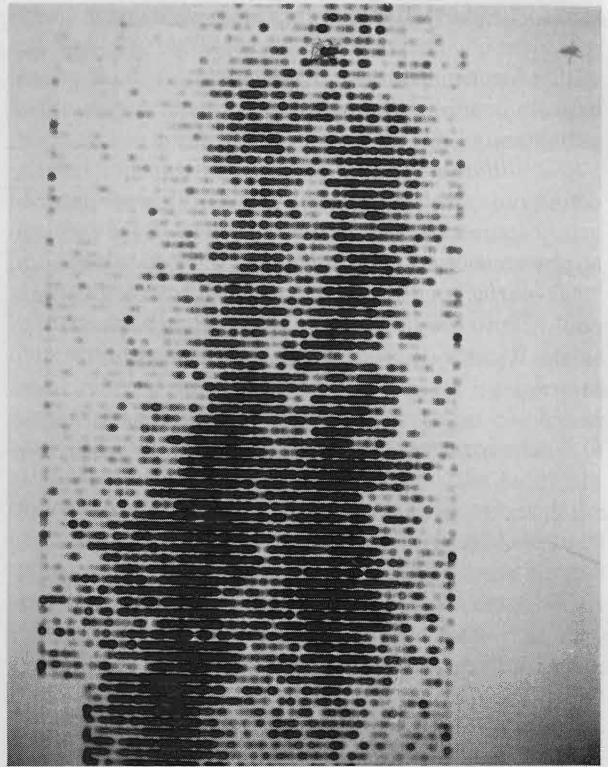


Fig 4—Misinjection in cisternography. Six hours after lumbar intrathecal administration of ^{131}I -Human Serum Albumin, no intracranial activity was detectable. This scan of the back shows the column of tracer split instead of as a solitary column. This is the appearance of subdural instead of subarachnoid injection.

studies, one may miss or have to equivocate on some lesions that often are well demonstrated on two- to four-hour studies (7,8).

8. *Abnormal pertechnetate brain scans following bone scans.* Several investigators have reported an altered appearance of radiopertechnetate brain scans performed one or two days following pyrophosphate or polyphosphate bone studies (9, 10, 11). This consisted of abnormally increased activity in the area of the sagittal sinus, transverse sinus, and choroid plexus (Fig 3). It has been postulated that tin attaches to red blood cells following bone imaging and subsequently administered pertechnetate undergoes intracellular reduction with labeling of the erythrocytes during the brain scan (10). It is suggested that brain scans should precede pyrophosphate bone scans or, alternately, the brain scan, as the second procedure, should be performed with ^{99m}Tc -DTPA.

9. *Problems with cisternography.* Only a couple of problems will be discussed here. The first relates to

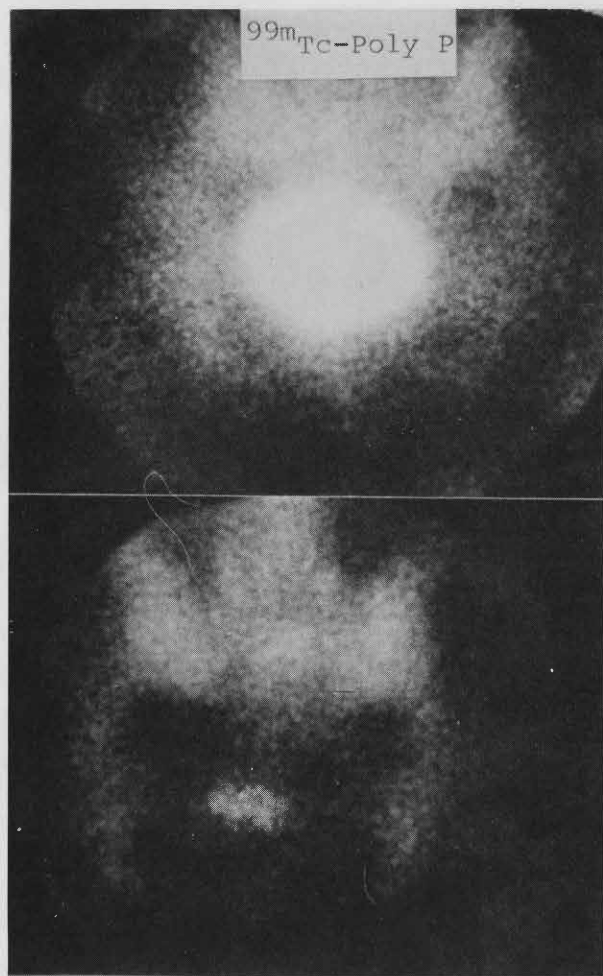


Fig 5—Degradation of bony pelvic structures by bladder activity. Upper posterior scintiphoto of pelvis was obtained 2 hours after administration of ^{99m}Tc -polyphosphate. Scatter from intense bladder activity severely degrades resolution of surrounding bony structures. Marked improvement in image quality is seen after patient voided and study was repeated (lower scintiphoto).

injection technique. If the intrathecally administered material (nowadays, primarily ^{111}In -DTPA) is placed outside the subarachnoid space, for example, sub- or epidural, no activity will reach the head. A scan of the back showing a split, rather than solitary, column of activity will confirm the suspicion of a faulty injection (Fig 4).

In studying cerebrospinal fluid leaks, it often is helpful to examine the patient in the same position in which the leak is occurring. A recent report showed an interesting artifact caused by residual ^{99m}Tc -pertechnetate activity from the previous day's brain scan (12). It was in the region of the nasopharynx or

mouth, creating the illusion of a CSF leak. Peaking solely on the higher gamma photon (247 keV) of ^{111}In would guard against this.

IV. Bone Imaging. Within the past three years, bone imaging has changed considerably primarily because of the introduction of ^{99m}Tc -labeled phosphate compounds. Prior to the "phosphate" era, Strontium-85 and subsequently ^{87m}Sr and ^{18}F were the radionuclides used.

1. Visualization of interfering colon activity with ^{85}Sr . This is the one difficulty associated with this older radiopharmaceutical that will be discussed. Because of a persistently high soft tissue and blood background, ^{85}Sr studies generally were performed at 2 to 3 days following injection. At this delayed time, the gastrointestinal tract represents the prime mode of excretion. Laxatives should be administered prior to performance of the study. On occasion, persistent colon activity might mimic osseous uptake if it is superimposed on a bony region such as the iliac wing.

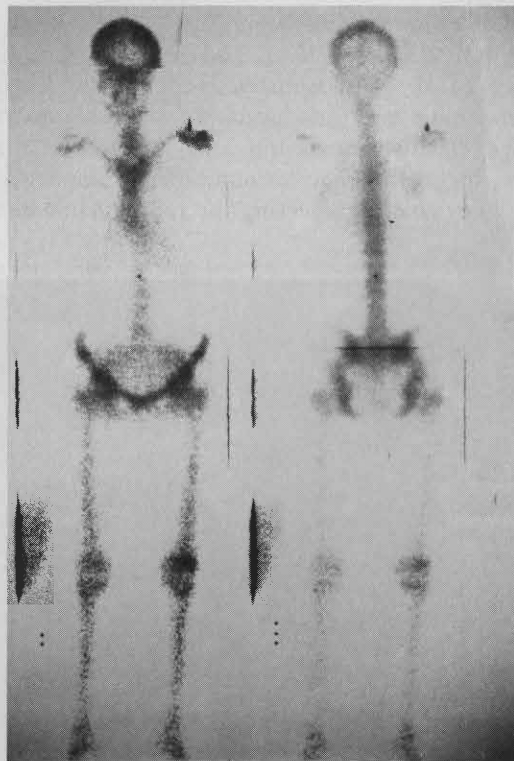


Fig 6—Diffuse bony metastases with relatively normal-appearing scan showing "missing kidney" sign. Patient with radiographically demonstrated diffuse bony metastases from breast carcinoma. Bony structures (except possibly the skull) appear normal on scan. The absence of kidney visualization is the prime clue that an abnormality is present (see text for further explanation).

Repeat study after enema or a couple of days later should help differentiate colon from true osseous activity.

2. *Diminished resolution of normal pelvic structures due to bladder activity.* This represents a basic problem in all imaging procedures. It is particularly well demonstrated in this area (Fig 5). The patient should be asked to void immediately prior to starting the scan. If bladder activity first presents as a problem after a study is performed, a repeat examination of the area after voiding should be obtained.

3. *Marginally active lesions missed due to excessive contrast enhancement.* In bone imaging we generally are searching for "hot" rather than "cold" areas. In setting up a study, the technologist may, inadvertently, use an extremely active region, such as the epiphysis in a child. This might prevent detection of an abnormal, but not intensely active, focus in another bony area in the same imaging field of view. Coned-down camera views of a suspicious area often are helpful.

4. *Occasional false-negative studies in purely lytic or diffuse blastic lesions.* The exact mechanism of uptake of ^{99m}Tc -phosphates is unknown. Several theories have been advanced which include ion exchange, chemisorption, and collagen uptake. In addition, blood flow and/or concentration appears to play a key role in delivering the radionuclide to the

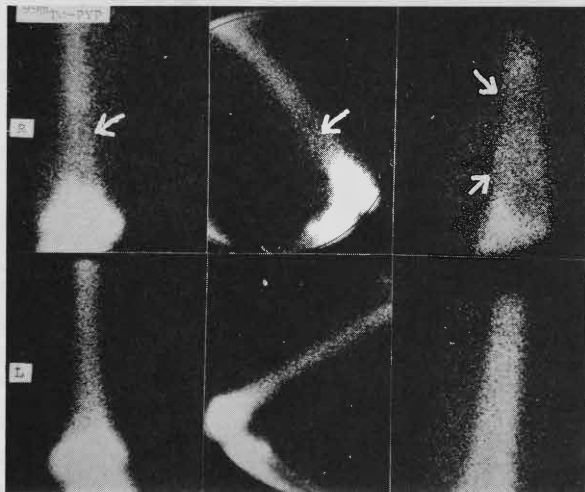


Fig 7—"Photon Deficient" bone lesion. The patient was a young girl with sickle cell disease and focal pain in distal right femur. Anterior, lateral, and anterior pinhole magnification views are shown for each distal femur. The area of mottled decreased activity ("cold" lesion) seen best on right lateral and right anterior pinhole collimator views (arrows) is characteristic of bone infarction.

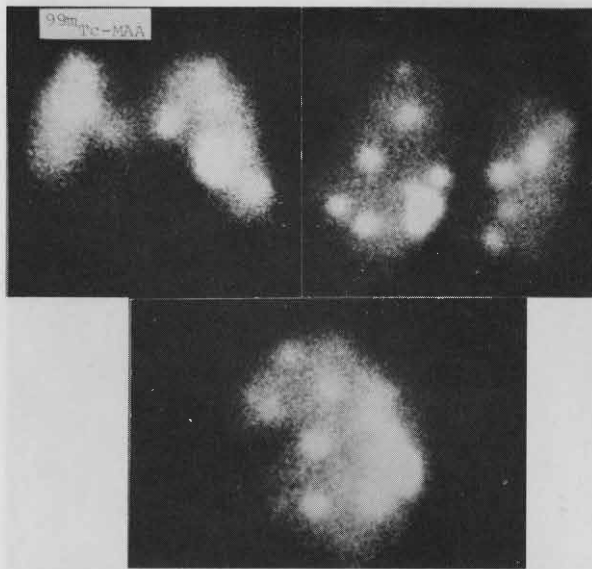


Fig 8—Radioactive pulmonary emboli. Anterior, posterior, and left lateral lung fields. (See text for explanation).

abnormal area. Most radiographically lytic lesions will have a significant reparative (blastic) component on histologic examination which would ensure their detection by radionuclide study. On occasion, a purely lytic lesion, for example, round cell sarcoma, may be relatively quiescent histologically and might, therefore, escape scintigraphic detection.

On the other hand, lesions that tend to have diffuse osseous involvement, for example, prostate or breast carcinomas, also might give false-negative studies (13). In bone scintigraphy, we depend upon a gradient between normal and abnormal uptake to detect a lesion. In diffuse, uniform involvement, all bones may be "hot" and such a gradient may not exist. One potential clue to the existence of such diffuse involvement is a diminution or absence of renal activity (Fig 6) (14). Approximately 30% to 50% of the administered dose of ^{99m}Tc -labeled phosphate should reach the skeleton with enough of the remaining activity going through the kidneys so that renal activity on a two-hour study should be fairly intense. Conceivably, lesions having hypermetabolic activity might utilize more than their usual share of tracer, thereby leaving only small amounts for the kidney. This finding has been useful to the author and should be looked for.

5. *Photon deficient ("cold") lesions.* On occasion, abnormalities on bone scan may present as "cold" rather than "hot" lesions (16). Complete interruption

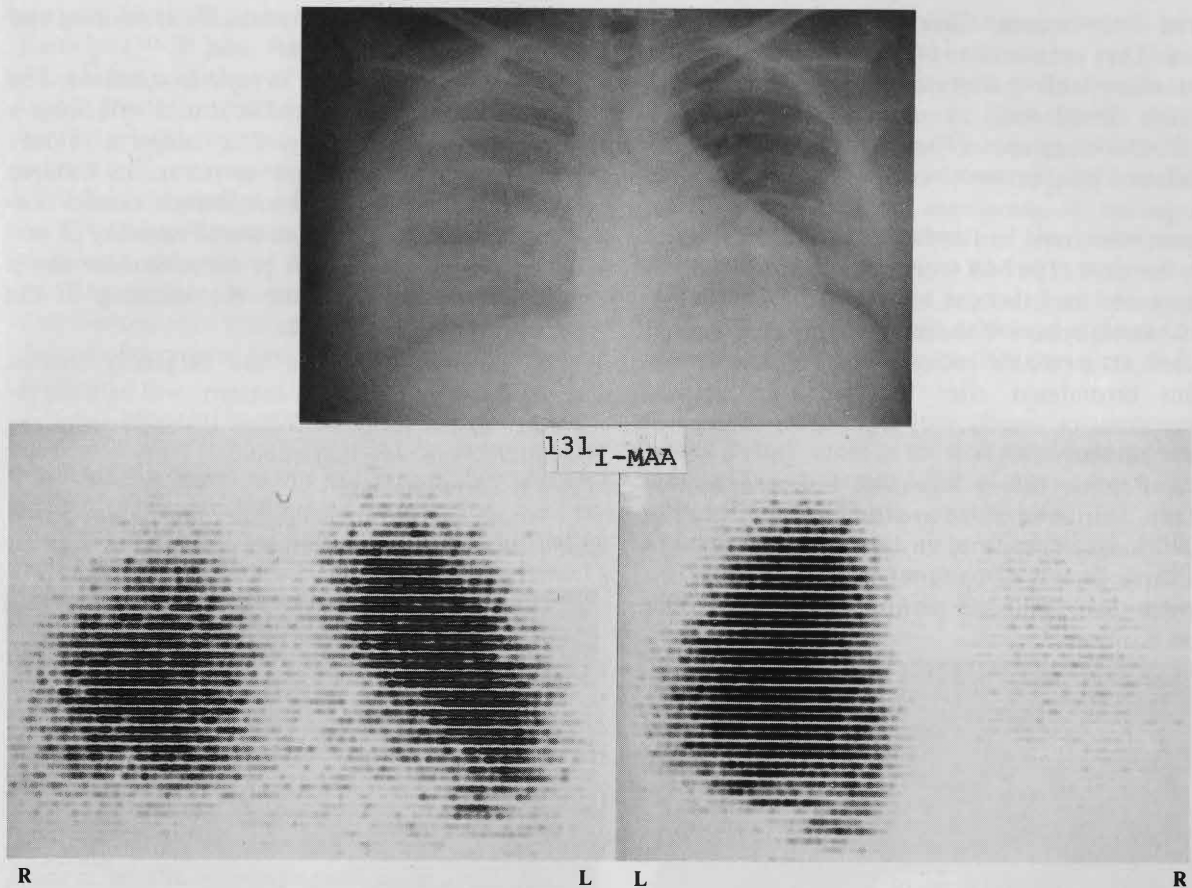


Fig 9—Interference of pleural fluid on dual-headed scanner study. Anterior scan (*lower left*) shows minimal diminution in right lung perfusion. Posterior scan (*lower right*) demonstrates much more severe apparent diminution in right lung activity due to interposed pleural fluid shown on chest x-ray (see text for explanation).

of blood supply, as in bone infarction, is a major cause of this finding (Fig 7). Other lesions such as occasional metastases and Legg-Calvé-Perthes' disease in children (17) also have shown this finding. In examining a bone scan, one, therefore, should be aware of this alternate evidence of an abnormal lesion.

6. *Asymmetries in chest activity due to radical mastectomy.* With reduced muscle mass following mastectomy, the osseous structures on the involved side appear more intense on the anterior scan (15). If the asymmetry appears on both anterior and posterior studies, a different explanation, such as pleural fluid, should be sought. Once again, a history, physical, and chest x-ray should solve any problems in this regard.

7. *Prosthesis, for example, pacemakers.* As in brain studies, overlying metallic or bulk objects such as pacemakers will attenuate radiation and create a

void on scan. The characteristic rounded shape of a pacemaker should help differentiate it from a possible "photon deficient" lesion (see section 5 above).

8. *Femoral vessel activity.* Some patients, particularly in older age groups, will show linear bands of increased activity medial to the femoral shafts. It is felt that, in some cases, this may represent actual changes in the femoral vessel wall. It may or may not be associated with radiographic evidence of calcification.

V. Lung Imaging.

1. *Radioactive "pulmonary emboli."* On occasion, large "hot" spots are seen on a lung scan (Fig 8) (18). This finding is most often encountered in situations where difficult venipunctures have allowed excessive red cell and macroaggregate mixture time in the syringe. Larger than usual aggregates (100μ to 1000μ) are formed which lodge in more proximal

arterial beds causing these radioactive pulmonary emboli. They are not of any clinical consequence, but do interfere with interpretation. Their typical appearance should easily be recognized.

2. *Macroaggregated hold-up on damaged endothelium.* Visualization of axillary vessels on the side of injection is sometimes noted; particularly in patients who have had indwelling venous catheters for a few days. The MAA or microspheres adhere to the irritated endothelium of these vessels. Thrombosed vessels behave in the same fashion. This cannot be used as a reliable indicator of lower extremity venous thrombosis after foot injection because venous stasis or insufficiency from other causes will behave similarly (19).

3. *Position during injection.* Macroaggregated albumin distributes along gravitational pathways in normal lungs. Therefore, an injection performed in an oblique, lateral, or upright position will result in a different scan than one performed in a supine or prone position.

4. *Perfusion changes due to pulmonary venous hypertension.* In patients with left ventricular failure and mitral heart disease, an anti-gravitational phenomenon results in redistribution of perfusion. The anterior and upper portions of the lung field will exhibit greater activity than the posterior and lower portions after a supine injection of MAA or microspheres. The degree of change generally is related to the severity of the pulmonary venous hypertension associated with the disease process.

5. *Free fluid distribution with dual-headed detectors.* Free pleural fluid usually gravitates to the dependent portion of a hemothorax which is that portion away from the detector head of an Anger camera or single-head rectilinear scanner. It will, therefore, have a minimal effect on the observed perfusion pattern. However, when a dual-headed detector is used, the fluid will be interposed between the lung and the lower detector. It often may cause a "dampening" effect and an impression of generalized decreased perfusion on the posterior scan only (Fig 9). Adherence to the cardinal rule of not interpreting a lung scan without a concurrently obtained chest radiograph should help avoid any problems.

6. *Size discrepancies with dual-headed detectors.* In interpreting lateral lung scans performed with dual-headed detectors, one should be aware of a "shrunk" appearance occasionally encountered in the "down" side of normal lungs. This is actually caused by the fact that the "up" side is hyperex-

panded. The "down" side is actually expanding and deflating more than the "up" side.

7. *Loss of activity due to right-to-left shunt.* The presence of right-to-left cardiac shunts will cause a loss of pulmonary activity. The finding of kidney activity should arouse some suspicion. In children with known large, right-to-left shunts, careful consideration should be given to the advisability of performing the lung scan. The prime reason for this is possible complications from the shunting of the macroaggregates to the brain.

In patients who have had surgically created shunts, details of the shunt anatomy will help the interpreter of the study determine if the particles are distributing the way they should.

VI. Liver Imaging.

1. *Altered distribution due to colloid particle size.* Technetium-99m-sulfur colloid particles (~ 100-400

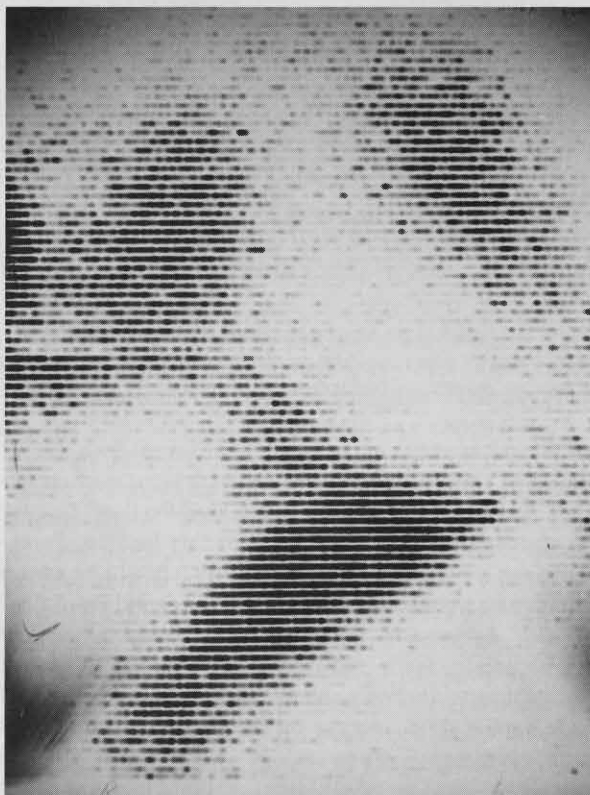


Fig 10—Subphrenic abscess simulating intrahepatic lesion. On this combined anterior liver-lung study, a massive concave defect is seen on right lateral border of hepatic activity. It appears as if some liver parenchyma is superior to the defect. The initial impression in this postoperative febrile patient was that of an intrahepatic abscess. At repeat laparotomy, the collection was completely extrahepatic and had displaced the liver medially.

$m\mu$) are 10 to 20 times larger than gold-198 colloid particles (10-20 $m\mu$). Although the vast majority of these larger particles still localize in the liver, a significantly greater proportion also will be phagocytized by the spleen's reticulo-endothelial system (20). In other words, we routinely image the spleen on ^{99m}Tc -sulfur colloid studies, whereas this was not the case on ^{198}Au scans. Increased splenic visualization was a significant indicator of diminished hepatic perfusion on ^{198}Au studies. Because of the normally different distribution, this finding is not as sensitive an indicator of decreased liver blood flow on ^{99m}Tc -colloid studies.

2. *Considerable anatomic variation in normal liver.* The liver scan is regarded by most nuclear medicine physicians as one of the most difficult to interpret. The tremendous variation that one encounters in the normal liver is a major contributing factor to this problem (21). Such variants as Riedel's lobe, left lobe thinning, high hemidiaphragms, interposed colon, and gallbladder fossa must be fully appreciated by the nuclear medicine physician before he can interpret hepatic scintigrams intelligently.

3. *Extrinsic pressure deformities from neighboring organs and structures.* Because of its great pliability, the liver's shape and configuration may be easily altered by normal variants or disease processes in neighboring organs and structures (22). Any process in the retroperitoneal area, for example, kidney or pancreas masses; intraperitoneal area, for example, high hepatic flexure of colon or subphrenic abscess; or intrahepatic area, for example, dilated gallbladder or bile ducts, can cause apparent hepatic defects that are often indistinguishable from true intrahepatic space-occupying lesions (Fig 10). An appreciation of this possibility and correlation with physical findings and other radiographic examinations are helpful in elucidating such problems.

4. *Apparent defects due to attenuation of the gamma photons.* As in other organ areas, overlying objects such as pacemakers, breast prostheses, and other objects may cause defects in the image. Physical examination at the time of study will assist the interpreter.

5. *"Pseudomasses" in cirrhosis and hepatitis.* Focal defects simulating space-occupying lesions may be encountered in patients with diffuse parenchymal problems such as cirrhosis or hepatitis. In cirrhosis, such defects have been attributed to fibrosis, atrophy, shunting, and nonfunctioning areas of regenerative nodulation (23). The potential existence of a

hepatoma in such a "cold" area presents a problem that generally may be solved by performing a radionuclide angiogram with pertechnetate and/or ^{75}Se -selenomethionine or ^{67}Ga -citrate metabolic studies. Hepatomas usually will be active with each of these tracers while almost all cirrhotic pseudomasses will not.

Less well appreciated is the pseudomass of hepatitis which appears to be due to nonuniform involvement of the disease process. Focal, severe swelling of the polygonal cells somehow appears to compromise function of much less prevalent R-E cells (24) (Fig 11).

6. *Hyperconcentration of colloid in occasional lesions.* "Hot" spots in the liver have been reported by several investigators. Most of these cases have been instances of venous obstruction, for example, superior vena caval, where umbilical collaterals crossing over the anterior surface of the liver in the interlobar area locally deposit a large amount of col-

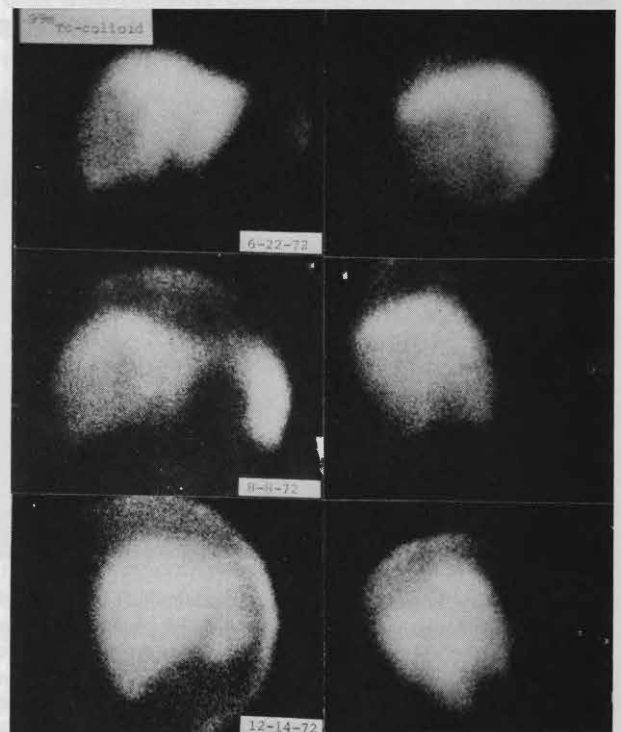


Fig. 11—Pseudomass in acute viral hepatitis. Upper row of ^{99m}Tc -sulfur colloid scintiphotos were performed in a 15-year-old, deeply jaundiced girl. An apparent space-occupying defect is seen in the right lobe. Liver biopsy of this area showed markedly swollen hepatocytes and a striking paucity of Kupffer's cells. The appearance was consistent with viral hepatitis. Middle and lower row of scintiphotos were obtained 6 weeks and 6 months later, respectively, and show a gradual return to normal.

loid (25). Two specific intrahepatic lesions that have shown "hot" rather than "cold" areas are abscess and hemangioma, the former because of R-E stimulation by the sepsis and the latter because of the markedly increased number of venous sinusoids with their associated R-E cells. Since we generally think of focal hepatic lesions as "cold" areas, one should remain attuned to this variant of the abnormal study. Recognition of its presence should make one feel a bit better after he or she has misinterpreted several hepatic masses.

7. *Renal concentration in ^{131}I -rose bengal studies.* Under normal circumstances, less than 5% of radioiodinated rose bengal is excreted by the kidneys. In patients with extrahepatic biliary obstruction or severe hepatic parenchymal disease, considerably more of the activity appears in the urine (26). This is particularly true in the former group of patients. Most likely it is free ^{131}I dissociated from the rose bengal that is appearing in the urine. With higher-than-normal levels of renal activity, the kidneys may be visualized on rose bengal abdominal scans (Fig

12). This finding must be differentiated from intestinal activity to avoid an erroneous interpretation of a patent biliary tract. This may be achieved by noting the following:

- a. Bilaterality of renal activity
- b. Same position, but more intense activity on follow-up studies
- c. Posterior position on lateral study
- d. Same position as kidneys on urogram or renal scintigram (if a, b, or c do not answer the question)

8. *Altered ^{131}I -rose bengal excretion patterns due to fistulae and shunts.* In naturally occurring, for example, cholecystocolonic, fistula or surgically produced shunts, for example, Longmeyer procedure, the rose bengal may escape the liver through an alternate pathway even though the biliary ducts may be obstructed. Careful observation of the time of transit as well as the pattern of extrahepatic activity are important considerations, as is the presence of a surgical history.

VII. Spleen Imaging.

1. *Bipartite spleen.* Similar to other organs, the spleen is subject to considerable variation in its normal shape and configuration. Lobulation and notches are frequent findings. On occasion, the spleen presents in two distinct pieces—the so-called "bipartite" spleen. In patients who have had left upper quadrant trauma, this may be a particularly troublesome finding that may require contrast angiography for clarification.

2. *Overlap of left lobe of liver with spleen simulating a defect.* In many patients the left hepatic lobe overlaps the upper splenic border and can cause an apparent defect on the superolateral border of the spleen (Fig 13). This is a very common pitfall that is frequently misinterpreted as a significant splenic lesion, particularly in trauma cases. Oblique views may not successfully separate the organs. We have found that a 30° caudad-angulated view with the patient in the prone position best separates the liver and spleen (27).

3. *Accessory spleen masked by overlying left lobe of the liver.* If a patient has had a therapeutic splenectomy for a hematological disorder, for example, idiopathic thrombocytopenia purpura, and continues to have difficulties, the presence of an accessory spleen must be excluded. Searches for such splenic tissue generally are undertaken with $^{99\text{m}}\text{Tc}$ -sulfur colloid as the initial tracer. Since this radiopharmaceutical is not spleen-specific, activity in the left




Fig 12—Renal concentration of radioiodinated rose bengal. Radioiodinated rose bengal scans on 68-year-old female with pancreatic carcinoma. A. 1-hr study demonstrates typical pattern of renal excretion (arrows). Because of its presence on this early scan, confusion with intestinal activity could easily lead to mistaken impression of patent biliary tract. 20/5 min clearance is 24% (normal = >35%). B. Serial scans, including this 24-hr study, reveal intensification, but no change in position of extrahepatic activity, confirming fact that activity represents kidneys (arrows). Upper half of right kidney is obscured by overlying hepatic activity. Failure of dye to leave liver supports impression of extrahepatic obstruction despite moderately impaired liver function (20/5-min blood clearance of 24%). C. 24-hr right lateral scan shows kidney in normal position posterior to liver.

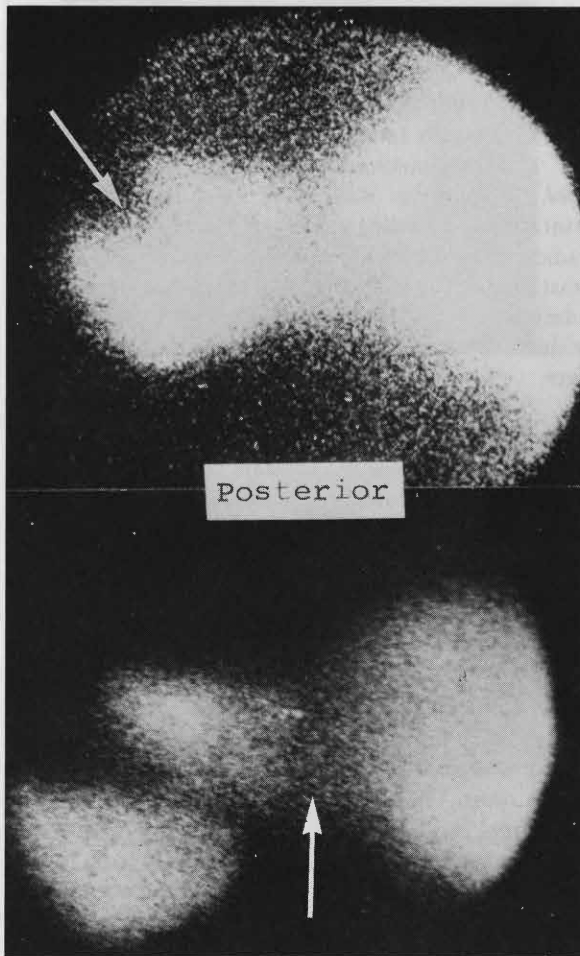


Fig 13—Overlap of left hepatic lobe and spleen simulating a splenic defect. On the initial study (*top*) in this 24-year-old male with a left upper quadrant stab wound, an apparent defect (*arrow*) is noted in the superolateral margin of the spleen. A slight obliquity (*bottom*) successfully separates left lobe of liver and spleen indicating that the suspect lesion was caused by an overlap of the two organs. Note that the medial portion of left lobe of liver (*arrow*) appears thinned due to attenuation of the photons by spine.

hepatic lobe conceivably might mask a splenunculus. Therefore, if the colloid study fails to demonstrate a spleen, a repeat study with ^{99m}Tc - or ^{51}Cr -labeled to heat denatured erythrocytes is needed. The tagged red cells are selectively sequestered by splenic tissue, and no interfering hepatic activity is encountered.

VIII. Pancreas Imaging.

1. *Poor visualization in fasting or debilitated patients with a normal pancreas.* Poor visualization of the pancreas on a ^{75}Se -selenomethionine study may reflect either disease or merely not enough pancreatic

stimulation (28). The patient should be prepared with overnight fasting followed by a well-balanced test meal. This will promote a profuse production of pancreatic enzymes and good uptake of the selenomethionine in most normal individuals (28). Absence of activity after such a protocol may be interpreted as pancreatic disease with a greater degree of confidence.

2. *Overlapping liver activity.* This is particularly troublesome in patients with hepatomegaly. Angling of the detector head towards the right upper quadrant as well as angulating the patient by raising the left flank and shoulder is a useful maneuver to correct this problem (28). The best solution is the use of subtraction technology, if it is available.

3. *Variations in shape and configuration of normal pancreas.* The pancreas may exist in the transverse, pistol-shape, oblique, or horseshoe configurations. Sometimes, a defect is present in the mid-body region as a result of the aorta or spine crossing over and thinning out the functioning tissue. Serial camera scintiphotos may show a changing concentration of activity in this region (28). Radionuclide aortography also may be used to correlate the aorta's position with the apparent defect on the scintigram.

IX. Kidney Imaging.

1. *Size discrepancies on erect and prone studies.* Ptotic kidneys may rotate on anteroposterior axis in the erect position. This foreshortening effect creates an impression of a smaller kidney when studied in the erect or sitting up position. Prone studies provide a safer means of assessing renal size.

2. *Free radiopertechnetate in the stomach when using ^{99m}Tc -labeled agents.* Most renal agents are prepared by reducing ^{99m}Tc from the +7 to +4 valence state with tin or some other suitable material. Pertechnetate (+7 state) may persist on rare occasions and its normal biologic localization in gastric mucosa may confuse interpretation of left kidney activity (29). Similarly, free ^{131}I may localize in the stomach on radioiodinated hippuran renal studies.

3. *Liver accumulation of chlormerodrin in azotemia.* When ^{197}Hg -chlormerodrin is used in renal studies, a small amount of hepatic activity usually is present. In azotemic patients, hepatic activity increases at the expense of renal excretion. Merging hepatic and renal activity may be misinterpreted as a large right kidney. As the azotemia worsens, the ability of the kidney to concentrate chlormerodrin is completely lost (Fig 14). At this stage, intense liver activity may be misinterpreted as a solitary right

kidney. In severe azotemia, ^{131}I -orthoiodohippurate is the agent of choice and its use should avoid any of the aforementioned problems (Fig 14).

4. *False results after urography or angiography.* High doses of organic iodides in the form of radiographic contrast media often cause transient changes in renal function that will effect the kidney's ability to concentrate subsequently administered radiopharmaceuticals. This is particularly true in patients with obstructive uropathy and, also, after

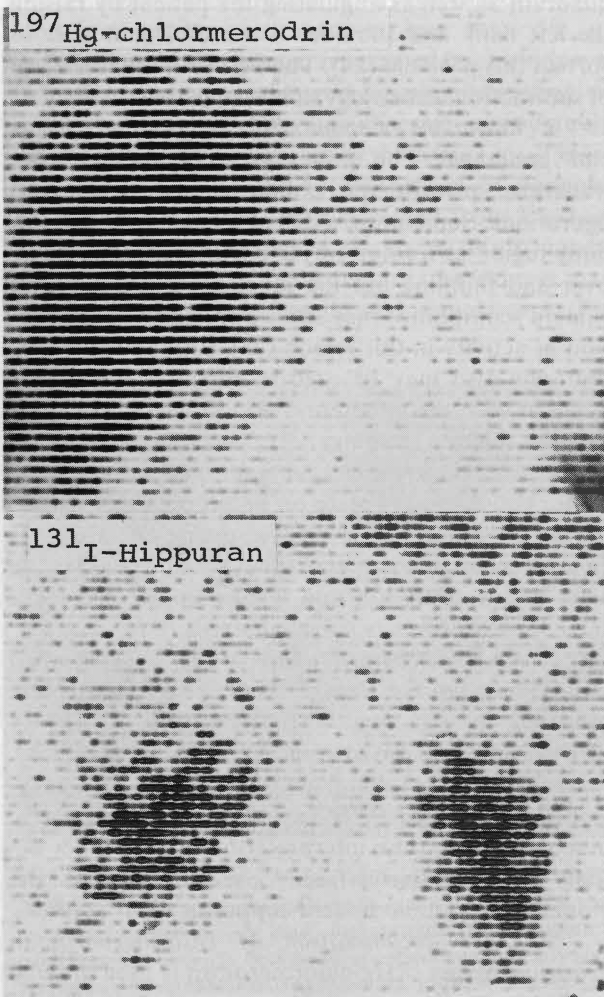


Fig 14—Pitfall in scanning azotemic patients with ^{197}Hg chlormerodrin. Patient shown had blood urea nitrogen of 112 mg/100 ml and plasma creatinine of 5.5 mg/100 ml. The ^{197}Hg chlormerodrin (*top*) has all been excreted by the liver. No renal concentration is evident. A frequent misinterpretation of this study is an enlarged solitary right kidney. The ^{131}I -Hippuran study (*bottom*) is successfully concentrated in both kidneys which are slightly smaller than normal.

selective renal artery studies. Optimally, the radionuclide studies should precede the radiographic studies. If this is not feasible, an interval of three or four days should be obtained between the studies.

X. Thyroid Imaging.

1. *Poor uptake and image due to saturated iodine pool.* In patients who have been taking iodide-containing medications or who have had radiographic examinations with organic iodide contrast media, the iodine pool is saturated. Subsequent administrations of tracer amounts of radioiodine within a few days will result in poor uptakes and images.

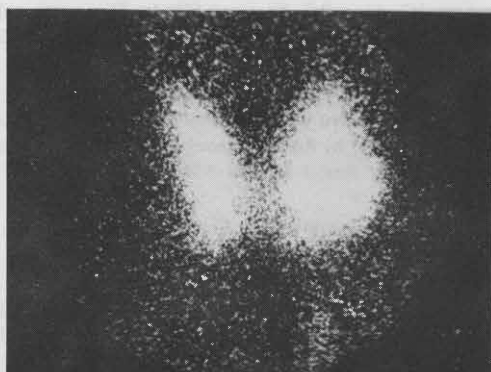2. *Failure to palpate nodules at the time the scan is performed.* A vague history of a palpated nodule in the right lobe is insufficient data to accurately assess whether the nodule is functional or not. Nodules should be palpated with the immobilized patient on the scanning bed. It should then be transcribed directly to the scan image. Such one-to-one relationships are best obtained with rectilinear scanner. By knowing exactly where a nodule is, one is able to offer an accurate interpretation. In order for a nodule to be considered functional, it must concentrate greater activity than the surrounding tissue.

3. *Pertechnetate uptake in nodules "cold" on iodine scans.* The categorization of functional or non-functional nodules is a radioiodine classification. Pertechnetate is handled quite differently from iodine in that the thyroid traps, but does not organify it. Therefore, a nodule may exhibit activity with the former, but not the latter (Fig 15). Such a nodule is to be considered "cold" and conceivably may represent a carcinoma. All nodules of the thyroid should be evaluated with radioiodine.

4. *Retrosternal functioning tissue unappreciated with low-energy gamma nuclides.* Iodine-125 has achieved some popularity as a thyroid imaging agent. Since it possesses very low energy imaging photons (~ 27 keV), it is inappropriate for studies in the thorax, for example, to search for retrosternal goiter. Although $^{99\text{m}}\text{Tc}$ -pertechnetate with its 140 keV gamma photon or ^{123}I with its 190 keV gamma photon may suffice, the 364 keV gamma photon of Iodine-131 appears best for this specific purpose.

XI. Blood Pool Studies.

1. *Excessive contrast enhancement on rectilinear scan cardiac blood pool studies.* The detection of a pericardial effusion using the rectilinear scanning method depends upon a comparison of the transverse diameters of the cardiac blood pool activity and the



$^{99m}\text{TcO}_4$ AT 30 min



$^{123}\text{I}^-$ AT 18 hr

Fig 15—Technetium-99m-pertechnetate concentrating in a thyroid nodule that is "cold" on Iodine-123 scan. Patient had palpable nodule in low lateral portion of left thyroid lobe. The radioiodine scintiphoto (*bottom*) shows this nodule to be hypofunctional ("cold"), while the pertechnetate study reveals good function in the same area. (See text for explanation). The nodule turned out to be an adenoma, but the diagnosis of carcinoma could not have been excluded.

cardiac silhouette as seen on a 6-foot supine chest radiograph. Excessive contrast enhancement can falsely "shrink" the size of the radionuclide blood pool and create the erroneous impression of an effusion in cases where it might not exist.

2. *Leakage of pertechnetate into pericardial effusions.* If ^{99m}Tc -pertechnetate is used as the tracer for blood pool studies, diagnostic images should be obtained within the first 20 to 30 minutes after injection. Studies obtained at one hour or later may be falsely negative since pertechnetate slowly diffuses into pericardial effusions masking the "halo" that is observed in positive camera studies (30).

3. *Poor labeling of Indium-113m chloride to transferrin in patients with receptor site saturation.*

When ^{113m}In chloride is used as the tracer for a blood pool study (particularly placental localization), it binds *in vivo* to transferrin, a serum globulin that is essential to the transport of iron. In cases of excessive iron ingestion or hemochromatosis, the transferrin receptor sites are bound. Subsequently administered ^{113m}In chloride will remain unbound and will appear in the kidneys. The desired blood pool will not be well visualized (31).

Case shown in Figure 8 courtesy Charles J. Blatt, MD.

Figure 11 is reprinted from the *Journal of Nuclear Medicine*, Vol. 14, No. 8, with permission of publisher.

Figure 13 is reproduced with permission from *Radiology* (110:419-425, 1973).

Figure 15 is reproduced from Atkins H, *The Thyroid in Clinical Scintillation Imaging*, Freeman LM, Johnson PJ (eds), New York, Grune & Stratton, 1975, by permission.

REFERENCES

- HARRIS CC: The care and feeding of medical nuclear instrumentation. *Semin Nucl Med* 3:225-238, 1973.
- FRIEDMAN BH, LOVEGROVE FTA, WAGNER HN JR: An unusual variant in cerebral circulation studies. *J Nucl Med* 15:363-364, 1974.
- ROSENTHALL L; *Intravenous Dynamic Nucleography of the Brain in Clinical Dynamic Function with Radionuclides*, M Croll (ed), New York, Appleton-Century-Crofts, 1972, p. 137-150.
- BARDFELD PA, HOLMES RA: Pertechnetate accumulation in the choroid plexus. *Am J Med Sci* 254:542-548, 1967.
- SILBERSTEIN AB, LEVY LM: ^{99m}Tc localization in the choroid plexus. *Radiology* 95:529-532, 1970.
- BERNSTEIN J, HOFFER PB: Use of the delayed brain scan in differentiating calvarial from cerebral lesions. *J Nucl Med* 15:681-684, 1974.
- RAMSEY RG, QUINN JL III: Comparison of accuracy between initial and delayed ^{99m}Tc -pertechnetate brain scans. *J Nucl Med* 13:(pt1) 131-134, 1972.
- HANDA J, NABESHIMA S, HANDA H, ET AL: Serial brain scanning with technetium 99m and scintillation camera. *Am J Roentgenol Radium Ther Nucl Med* 106:708-723, 1969.
- WALKER AG: Effect of tc-99m-sn bone scan agents on subsequent pertechnetate brain scans, abstracted. *J Nucl Med* 16:579, 1975.
- CHANDLER WM, SHUCK LD: Abnormal technetium-99m pertechnetate imaging following stannous pyrophosphate bone imaging, abstracted. *J Nucl Med* 16:518-519, 1975.

11. KHENTIGEN A, GARRETT M, LUM D, ET AL: Effect of prior administration of sn (II) complexes used in nuclear medicine on in vivo distribution of subsequently administered tc-99m pertechnetate and tc-99m compounds, abstracted. *J Nucl Med* 16:541, 1975.
12. COWAN RJ, MURPHY MP, MAYNARD CP: Production of cerebrospinal fluid leak artifact by residual ^{99m}Tc-pertechnetate. *J Nucl Med* 16:434, 1975.
13. THRUPKAEW AK, HENKIN RE, QUINN JL III: False negative bone scans in disseminated metastatic disease. *Radiology* 113: 383-386, 1974.
14. SY WM, PATEL D, FAUNCE H: Significance of absent or faint kidney sign on bone scan. *J Nucl Med* 16:454-456, 1975.
15. ISITMAN AT, KOMAKI S, HOLMES RA: A benign uptake of ^{99m}Tc-polyphosphate after radical mastectomy. *Radiology* 110:159-161, 1974.
16. GOERGEN TG, ALAZRAKI NP, HALPERN SE, ET AL: "Cold" bone lesions: A newly recognized phenomenon of bone imaging. *J Nucl Med* 15(pt 2): 1120-1124, 1974.
17. DANIGELIS JA, FISHER RL, OZONOFF MB, ET AL: ^{99m}Tc-polyphosphate bone imaging in legg-perthes disease. *Radiology* 115:407-414, 1975.
18. KONTZEN FN, BESCHI RJ, PITTMAN JA: Radioactive pulmonary emboli. *Alabama J Med Sci* 8:27-29, 1971.
19. ROSENTHALL L, GREYSON ND: Observations on the use of ^{99m}Tc albumin macroaggregates for detection of thrombophlebitis. *Radiology* 94:413-416, 1970.
20. DOBSON EL, JONES HB: The behavior of intravenously injected particulate material: Its rate of disappearance from the blood stream as a measure of liver blood flow. *Acta Med Scand* suppl 273, pp 1-71, 1952.
21. MCAFEE JG, AUSE RG, WAGNER HN JR: Diagnostic value of scintillation scanning of the liver. *Arch Intern Med* 116:95-110, 1965.
22. FREEMAN LM, MENG CH, JOHNSON PM, ET AL: False positive liver scans caused by disease processes in adjacent organs and structures. *Br J Radiol* 42:651-656, 1969.
23. JOHNSON PM, SWEENEY WA: The false-positive hepatic scan. *J Nucl Med* 8:451-460, 1967.
24. KOENIGSBERG M, FREEMAN LM: Intrahepatic focal lesion in acute viral hepatitis. *J Nucl Med* 14(pt 2):612-614, 1973.
25. HOLMQUEST DL, BURDINE JA: Caval-portal shunting as a cause of a focal increase in radiocolloid uptake in normal livers. *J Nucl Med* 14:348-351, 1973.
26. FREEMAN LM, KAY CJ, DERMAN A: Renal excretion of radioiodinated rose bengal—A pitfall in the interpretation of rose bengal abdominal scans. *J Nucl Med* 9:227-232, 1968.
27. LUTZKER L, KOENIGSBERG M, MENG CH, ET AL: Role of radionuclide imaging in spleen trauma. *Radiology* 110:419-425, 1974.
28. MIALE A JR, RODRIGUEZ-ANTUNEZ A, GILL WM JR: Pancreas scanning after ten years. *Semin Nucl Med* 2:201-219, 1972.
29. MCKUSICK KA, MALMUD LS, KIRCHNER PT, ET AL: An interesting artifact in radionuclide imaging of kidneys. *J Nucl Med* 14:113-114, 1973.
30. CHRISTENSEN EE, BONTE FJ: The relative accuracy of echocardiography, intravenous co₂ studies, and blood-pool scanning in detecting pericardial effusions in dogs. *Radiology* 91:265-270, 1968.
31. RICHARDS AG, MORRISON RT: Unexpected renal scanning during placental scanning with ^{113m}In. *Radiology* 104:611, 1972.

how big a dose will now bring relief if it is a narcotic?

"Tolerance is an ever-present hazard to continued use of narcotics. . . . The very first dose diminishes the effects of subsequent doses." ¹ And as a narcotic

¹Quoted in M. L. A. Text of Narcotics and Dependence, *Parsons and Sons*, 1952, p. 10.

Tablet you provide good pain relief. Talwin can be compared to other analgesic drugs. The 50 mg. tablet is equivalent to 100 mg. of morphine. How periods such as that of the narcotic, you would expect with narcotics. There should be fewer "adverse effects" on the way of life.

Tolerance may develop to the analgesic effect of Talwin Tablets.

Dependence may develop during three years of wide clinical use. There have been a few reports of dependence and withdrawal symptoms with orally administered Talwin. Patients with a history of drug dependence should be under close supervision when receiving Talwin.

In prescribing Talwin for chronic use, the physician should take precautions to avoid increased misuse by the patient and to prevent the use of the drug in addiction or for other than the relief of pain.

Generally well tolerated by most patients. Intra-arterial injection may cause hypotension or hypotension. Intra-arterial injection may cause respiratory depression or urinary retention. Sedation, drowsiness, or confusion. Acute, transient CNS effects, described in product information on following page, have occurred in rare instances following the use of Talwin Tablets. If dizziness, orthostatic hypotension, nausea, drowsiness, or confusion occur, these effects may decrease or disappear after the first few doses.

Correction Notice: On p. 76 of the MCV/Q 11:2, 1975, *Nuclear Medicine—Part I*, the first sentence of section 5 should have read, "Adequate assessment of both single and multiple nodules in the thyroid gland require that a scan be performed after the administration of ¹³¹I (4), ¹²³I (5) if available, or ^{99m}Tc (6)."

Talwin 50 mg. Tablets
pentazocine

after taking a potent analgesic 360 times in 3 months...





**after taking a
potent analgesic
360 times
in 3 months...**

how big a dose will now bring relief if it is a narcotic?

"Tolerance is an ever-present hazard to continued use of narcotics. . . . The very first dose diminishes the effects of subsequent doses."¹ And, as increasing amounts of narcotics are required to control pain, distressing adverse effects—lethargy, hypotension, constipation, etc.—can needlessly debilitate the patient.

1. Sadove, M. S.: A look at narcotic and non-narcotic analgesics, *Postgrad. Med.* 49:102, June 1971.

how big a dose will now bring relief if it is Talwin®?

Chances are, the same 50 mg. Talwin Tablet you prescribe originally will continue to provide good pain relief. Talwin can be compared to codeine in analgesic efficacy: one 50 mg. tablet appears equivalent in analgesic effect to 60 mg. (1 gr.) of codeine. However, patients receiving Talwin Tablets for prolonged periods face fewer of the consequences you've come to expect with narcotics. There should be fewer "adverse effects" on her way of life.

Tolerance rare: Tolerance to the analgesic effect of Talwin Tablets is rare.

Dependence rare: *During three years of wide clinical use, there have been a few reports of dependence and of withdrawal symptoms with orally administered Talwin. Patients with a history of drug dependence should be under close supervision while receiving Talwin orally.*

*In prescribing Talwin for chronic use, the physician should take precautions to avoid increases in dose by the patient and to prevent the use of the drug in anticipation of pain rather than for the relief of pain.**

Generally well tolerated by most patients*: Infrequently causes decrease in blood pressure or tachycardia; rarely causes respiratory depression or urinary retention; seldom causes diarrhea or constipation. Acute, transient CNS effects, described in product information on following page, have occurred in rare instances following the use of Talwin Tablets. If dizziness, lightheadedness, nausea or vomiting are encountered, these effects may decrease or disappear after the first few doses.

*See important product information on next page for adverse reactions, patient selection, prescribing and precautionary recommendations.

**in chronic pain
of moderate to severe intensity**

Talwin® 50 mg.
Tablets
brand of
pentazocine
(as hydrochloride)

how big a dose will now bring relief if it is a narcotic?

"Tolerance is an ever-present hazard to continued use of narcotics. . . . The very first dose diminishes the effects of subsequent doses."¹ And, as increasing amounts of narcotics are required to control pain, distressing adverse effects—lethargy, hypotension, constipation, etc.—can needlessly debilitate the patient.

1.Sadove, M. S.: A look at narcotic and non-narcotic analgesics, *Postgrad. Med.* 49:102, June 1971.

how big a dose will now bring relief if it is Talwin®?

Chances are, the same 50 mg. Talwin Tablet you prescribe originally will continue to provide good pain relief. Talwin can be compared to codeine in analgesic efficacy: one 50 mg. tablet appears equivalent in analgesic effect to 60 mg. (1 gr.) of codeine. However, patients receiving Talwin Tablets for prolonged periods face fewer of the consequences you've come to expect with narcotics. There should be fewer "adverse effects" on her way of life.

Tolerance rare: Tolerance to the analgesic effect of Talwin Tablets is rare.

Dependence rare: *During three years of wide clinical use, there have been a few reports of dependence and of withdrawal symptoms with orally administered Talwin. Patients with a history of drug dependence should be under close supervision while receiving Talwin orally.*

*In prescribing Talwin for chronic use, the physician should take precautions to avoid increases in dose by the patient and to prevent the use of the drug in anticipation of pain rather than for the relief of pain.**

Generally well tolerated by most patients*: Infrequently causes decrease in blood pressure or tachycardia; rarely causes respiratory depression or urinary retention; seldom causes diarrhea or constipation. Acute, transient CNS effects, described in product information on following page, have occurred in rare instances following the use of Talwin Tablets. If dizziness, lightheadedness, nausea or vomiting are encountered, these effects may decrease or disappear after the first few doses.

*See important product information on next page for adverse reactions, patient selection, prescribing and precautionary recommendations.

**in chronic pain
of moderate to severe intensity**

Talwin® 50 mg.
Tablets
brand of
pentazocine
(as hydrochloride)



in chronic pain of moderate to severe intensity



**Talwin® Tablets brand of pentazocine (as hydrochloride)
Analgesic for Oral Use**

Indication: For the relief of moderate to severe pain.

Contraindication: Talwin should not be administered to patients who are hypersensitive to it.

Warnings: Drug Dependence. There have been instances of psychological and physical dependence on parenteral Talwin in patients with a history of drug abuse and, rarely, in patients without such a history. Abrupt discontinuance following the extended use of parenteral Talwin has resulted in withdrawal symptoms. There have been a few reports of dependence and of withdrawal symptoms with orally administered Talwin. Patients with a history of drug dependence should be under close supervision while receiving Talwin orally.

In prescribing Talwin for chronic use, the physician should take precautions to avoid increases in dose by the patient and to prevent the use of the drug in anticipation of pain rather than for the relief of pain.

Head Injury and Increased Intracranial Pressure. The respiratory depressant effects of Talwin and its potential for elevating cerebrospinal fluid pressure may be markedly exaggerated in the presence of head injury, other intracranial lesions, or a preexisting increase in intracranial pressure. Furthermore, Talwin can produce effects which may obscure the clinical course of patients with head injuries. In such patients, Talwin must be used with extreme caution and only if its use is deemed essential.

Usage in Pregnancy. Safe use of Talwin during pregnancy (other than labor) has not been established. Animal reproduction studies have not demonstrated teratogenic or embryotoxic effects. However, Talwin should be administered to pregnant patients (other than labor) only when, in the judgment of the physician, the potential benefits outweigh the possible hazards. Patients receiving Talwin during labor have experienced no adverse effects other than those that occur with commonly used analgesics. Talwin should be used with caution in women delivering premature infants.

Acute CNS Manifestations. Patients receiving therapeutic doses of Talwin have experienced, in rare instances, hallucinations (usually visual), disorientation, and confusion which have cleared spontaneously within a period of hours. The mechanism of this reaction is not known. Such patients should be very closely observed and vital signs checked. If the drug is reinstated it should be done with caution since the acute CNS manifestations may recur.

Usage in Children. Because clinical experience in children under 12 years of age is limited, administration of Talwin in this age group is not recommended.

Ambulatory Patients. Since sedation, dizziness, and occasional euphoria have been noted, ambulatory patients should be warned not to operate machinery, drive cars, or unnecessarily expose themselves to hazards.

Precautions: Certain Respiratory Conditions. Although respiratory depression has rarely been reported after oral administration of Talwin, the drug should be administered with caution to patients with respiratory depression from any cause, severely limited respiratory reserve, severe bronchial asthma and other obstructive respiratory conditions, or cyanosis.

Impaired Renal or Hepatic Function. Decreased metabolism of the drug by the liver in extensive liver disease may predispose to accentuation of side effects. Although laboratory tests have not indicated that Talwin causes or increases renal or hepatic impairment, the drug should be administered with caution to patients with such impairment.

Myocardial Infarction. As with all drugs, Talwin should be used with caution in patients with myocardial infarction who have nausea or vomiting.

Biliary Surgery. Until further experience is gained with the effects

of Talwin on the sphincter of Oddi, the drug should be used with caution in patients about to undergo surgery of the biliary tract.

Patients Receiving Narcotics. Talwin is a mild narcotic antagonist. Some patients previously given narcotics, including methadone for the daily treatment of narcotic dependence, have experienced withdrawal symptoms after receiving Talwin.

CNS Effect. Caution should be used when Talwin is administered to patients prone to seizures; seizures have occurred in a few such patients in association with the use of Talwin although no cause and effect relationship has been established.

Adverse Reactions: Reactions reported after oral administration of Talwin include **gastrointestinal:** nausea, vomiting; infrequently constipation; and rarely abdominal distress, anorexia, diarrhea. **CNS effects:** dizziness, lightheadedness, sedation, euphoria, headache; infrequently weakness, disturbed dreams, insomnia, syncope, visual blurring and focusing difficulty, hallucinations (see **Acute CNS Manifestations** under **WARNINGS**); and rarely tremor, irritability, excitement, tinnitus. **Autonomic:** sweating; infrequently flushing; and rarely chills. **Allergic:** infrequently rash; and rarely urticaria, edema of the face. **Cardiovascular:** infrequently decrease in blood pressure, tachycardia. **Hematologic:** rarely depression of white blood cells (especially granulocytes), usually reversible and usually associated with diseases or other drugs which are known to cause such changes, moderate transient eosinophilia. **Other:** rarely respiratory depression, urinary retention, toxic epidermal necrolysis.

Dosage and Administration: Adults. The usual initial adult dose is 1 tablet (50 mg.) every three or four hours. This may be increased to 2 tablets (100 mg.) when needed. Total daily dosage should not exceed 600 mg.

When antiinflammatory or antipyretic effects are desired in addition to analgesia, aspirin can be administered concomitantly with Talwin.

Children Under 12 Years of Age. Since clinical experience in children under 12 years of age is limited, administration of Talwin in this age group is not recommended.


Duration of Therapy. Patients with chronic pain who have received Talwin orally for prolonged periods have not experienced withdrawal symptoms even when administration was abruptly discontinued (see **WARNINGS**). No tolerance to the analgesic effect has been observed. Laboratory tests of blood and urine and of liver and kidney function have revealed no significant abnormalities after prolonged administration of Talwin.

Overdosage: Manifestations. Clinical experience with Talwin overdosage has been insufficient to define the signs of this condition.

Treatment. Oxygen, intravenous fluids, vasopressors, and other supportive measures should be employed as indicated. Assisted or controlled ventilation should also be considered. Although nalorphine and levallorphan are *not* effective antidotes for respiratory depression due to overdosage or unusual sensitivity to Talwin, parenteral naloxone (Narcan®, available through Endo Laboratories) is a specific and effective antagonist.

Talwin is not subject to narcotic controls.

How Supplied: Tablets, peach color, scored. Each tablet contains Talwin (brand of pentazocine) as hydrochloride equivalent to 50 mg. base. Bottles of 100.

Winthrop Laboratories, New York, N.Y. 10016 

50 mg. Tablets

Talwin®
brand of
pentazocine

(as hydrochloride) (1623MA)

The American Association for the Study of Headache
announces

THE ELEVENTH ANNUAL HAROLD G. WOLFF, M.D. LECTURE AWARD

which will be awarded to the physician who submits the best original paper on headache, head pain, or on the nature of pain itself. The paper may be concerned with basic research, clinical studies, or both. All physicians, including those in training as fellows or residents are eligible. Winner of the 1975 award is Ottar Sjaastad, M.D., Oslo, Norway for his paper, "Histamine and Its Relation to Vascular Headache, With Particular Reference to Cluster Headache"

A prize of \$1,000 will be awarded to the recipient of the lectureship, and he will be invited to present the paper at the annual meeting of the American Association for the Study of Headache. The next annual meeting will be held at the Sheraton-Dallas Hotel in Dallas, Texas on June 26-27, 1976.

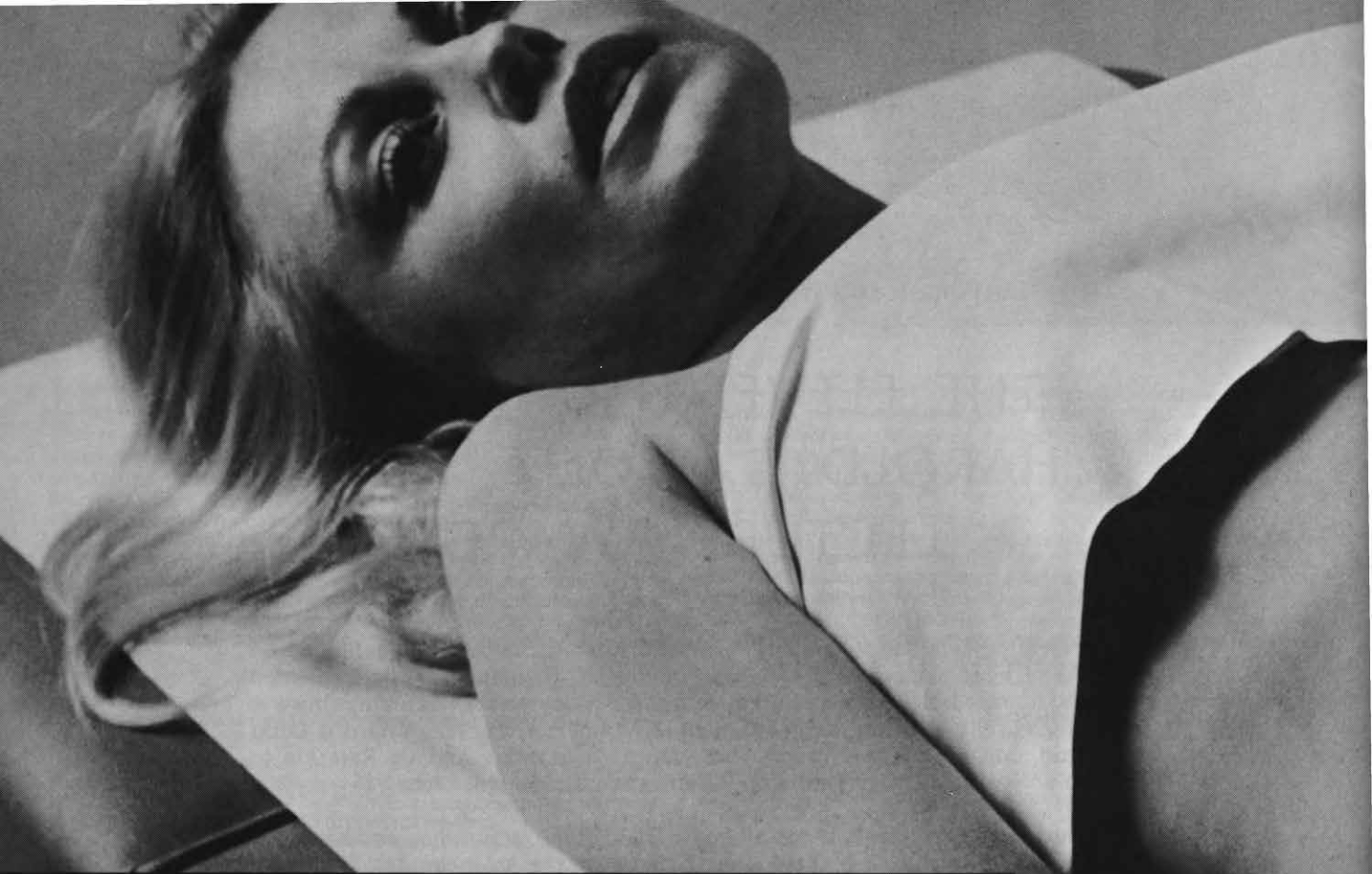The papers will be judged by the Editor and Associate Editors of the journal, Headache. Papers should be submitted in duplicate in accordance with that journal's editorial instructions. Those papers which do not win the prize, but which are deemed worthy of publication may be published in the journal at the discretion of the editorial board. Similarly, authors of these papers may be invited to present their work at the annual meeting, at the discretion of the program committee. The judges reserve the right not to make the award if no paper submitted is considered worthy of it.

Papers should be submitted to:

Otto Appenzeller, M.D., Ph.D.
Department of Neurology
UNM School of Medicine
1007 Stanford Drive N.E.
Albuquerque, N.M. 87131

Deadline for submission of papers is March 1, 1976.

The support of Sandoz Pharmaceuticals is gratefully acknowledged.




A service to medical education from A. H. Robins:

Excerpted from Volume 2

of the
G.I. Series

on physical examination
of the abdomen:

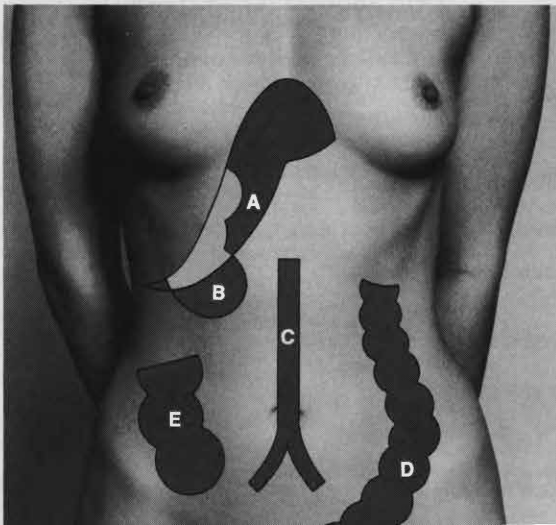
The A. H. Robins G.I. Series consists of six booklets, designed to provide a quick, yet comprehensive review of basic procedures and practices in G.I. medicine—with particular emphasis on the physical examination as performed in the office or at bedside. If you have teaching responsibilities, limited quantities are available: Part 1—*Inspection*, Part 2—*Palpation*, Part 3—*Percussion*, Part 4—*Auscultation*, Part 5—*Abdominal Pain* and Part 6—*Differential Diagnosis of Abdominal Disorders*. Write to: The Medical Department, A. H. Robins Company, 1407 Cummings Drive, Richmond, Virginia 23220.

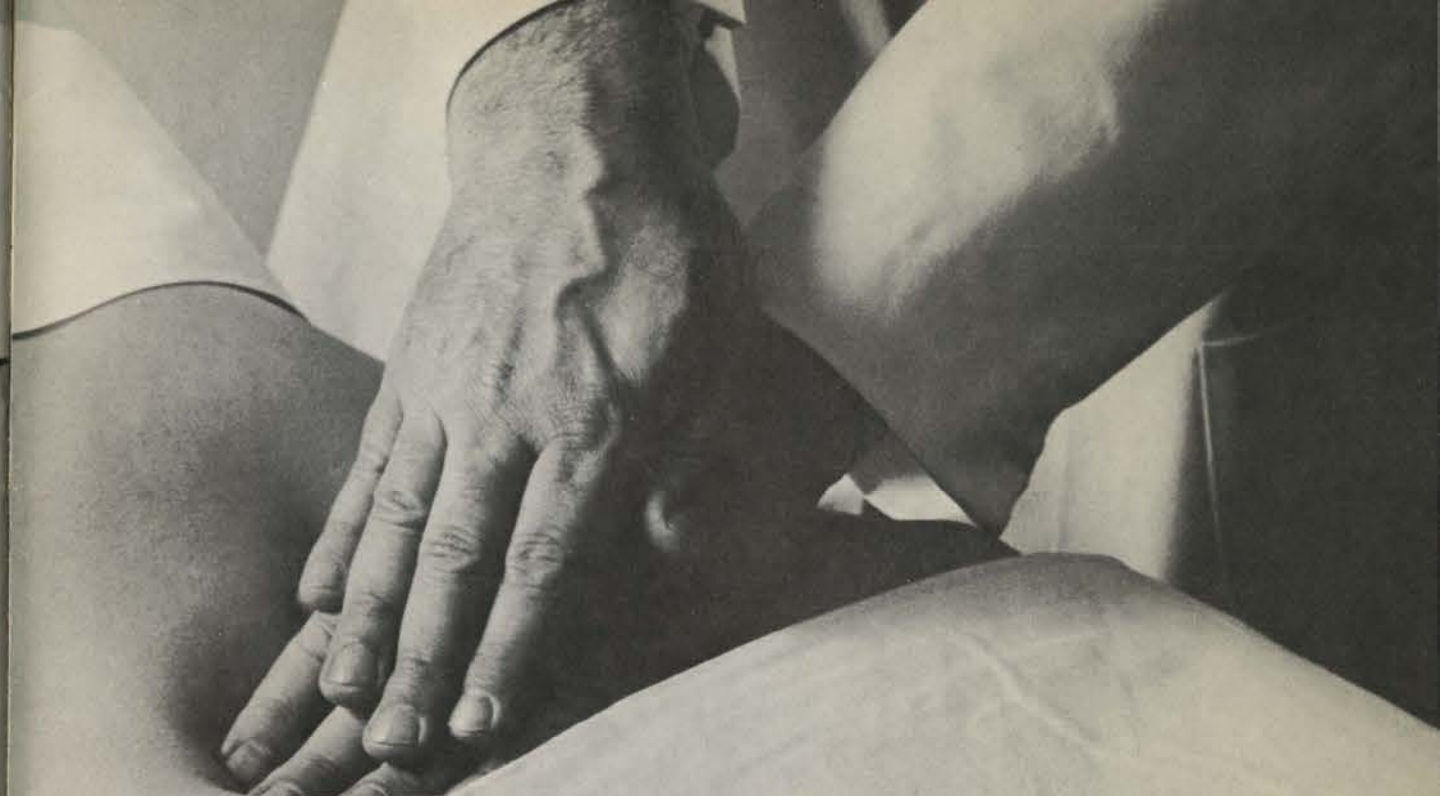
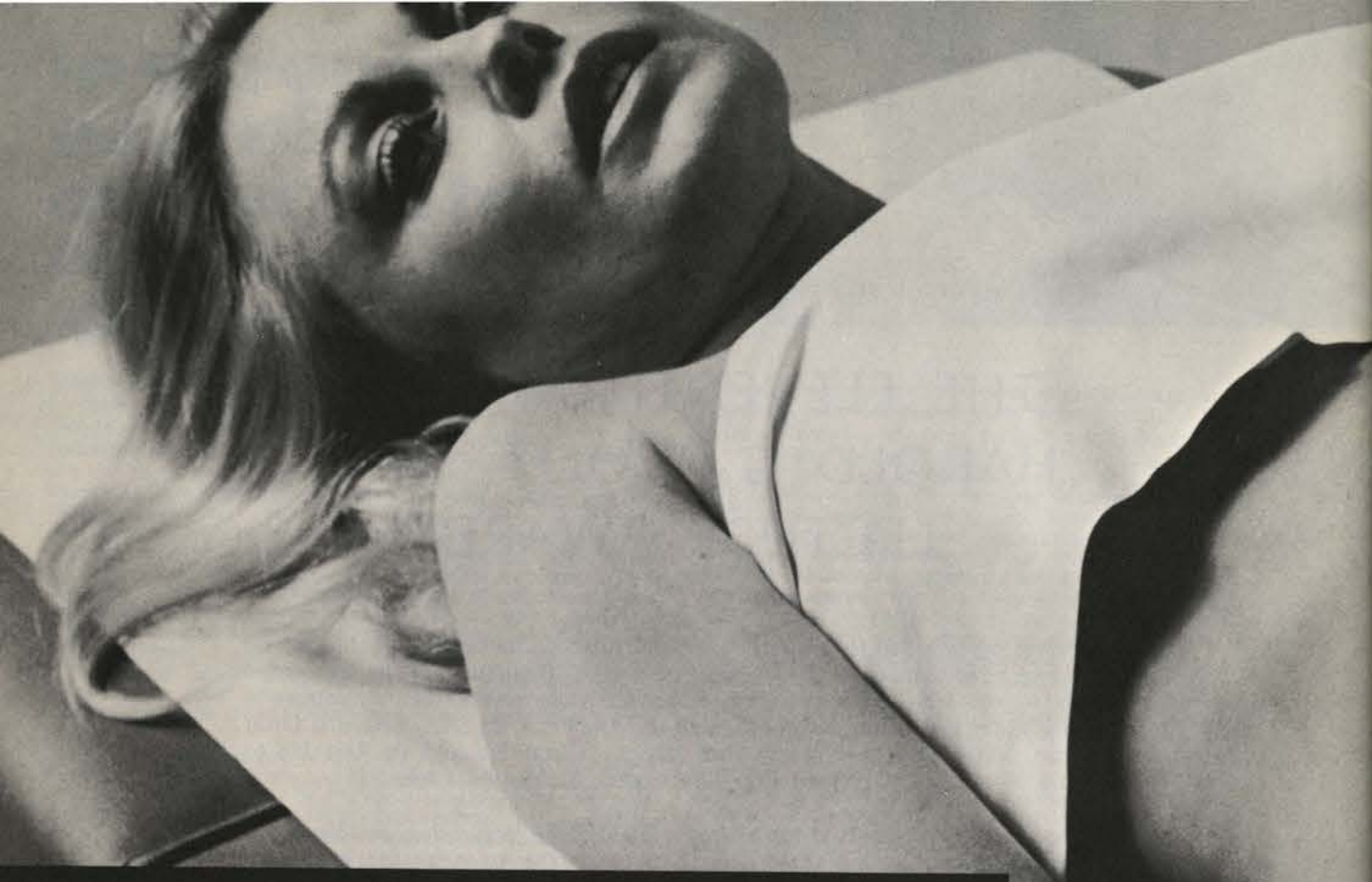
Normally palpable organs:

the edge of the liver descending, on inspiration, below the costal margin (A); the lower pole of the right kidney (B); the abdominal aorta (C); the descending colon and the sigmoid (D); the ascending colon (E); and occasionally the bladder (though rising of this organ beyond the pubis does not necessarily indicate disease).

Impossible to outline, unless diseased, distended or enlarged: the gallbladder, pancreas, stomach, small intestine, transverse colon and spleen.





A service to medical education from A. H. Robins:

Excerpted from Volume 2

G.I. Series

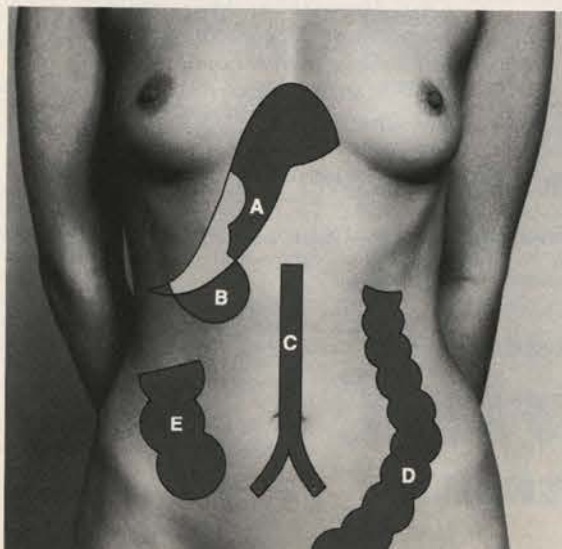
on physical examination
of the abdomen:

The A. H. Robins G.I. Series consists of six booklets, designed to provide a quick, yet comprehensive review of basic procedures and practices in G.I. medicine—with particular emphasis on the physical examination as performed in the office or at bedside. If you have teaching responsibilities, limited quantities are available: Part 1—*Inspection*, Part 2—*Palpation*, Part 3—*Percussion*, Part 4—*Auscultation*, Part 5—*Abdominal Pain* and Part 6—*Differential Diagnosis of Abdominal Disorders*. Write to: The Medical Department, A. H. Robins Company, 1407 Cummings Drive, Richmond, Virginia 23220.



Normally palpable organs:

the edge of the liver descending, on inspiration, below the costal margin (A); the lower pole of the right kidney (B); the abdominal aorta (C); the descending colon and the sigmoid (D); the ascending colon (E); and occasionally the bladder (though rising of this organ beyond the pubis does not necessarily indicate disease).



Impossible to outline, unless diseased, distended or enlarged: the gallbladder, pancreas, stomach, small intestine, transverse colon and spleen.

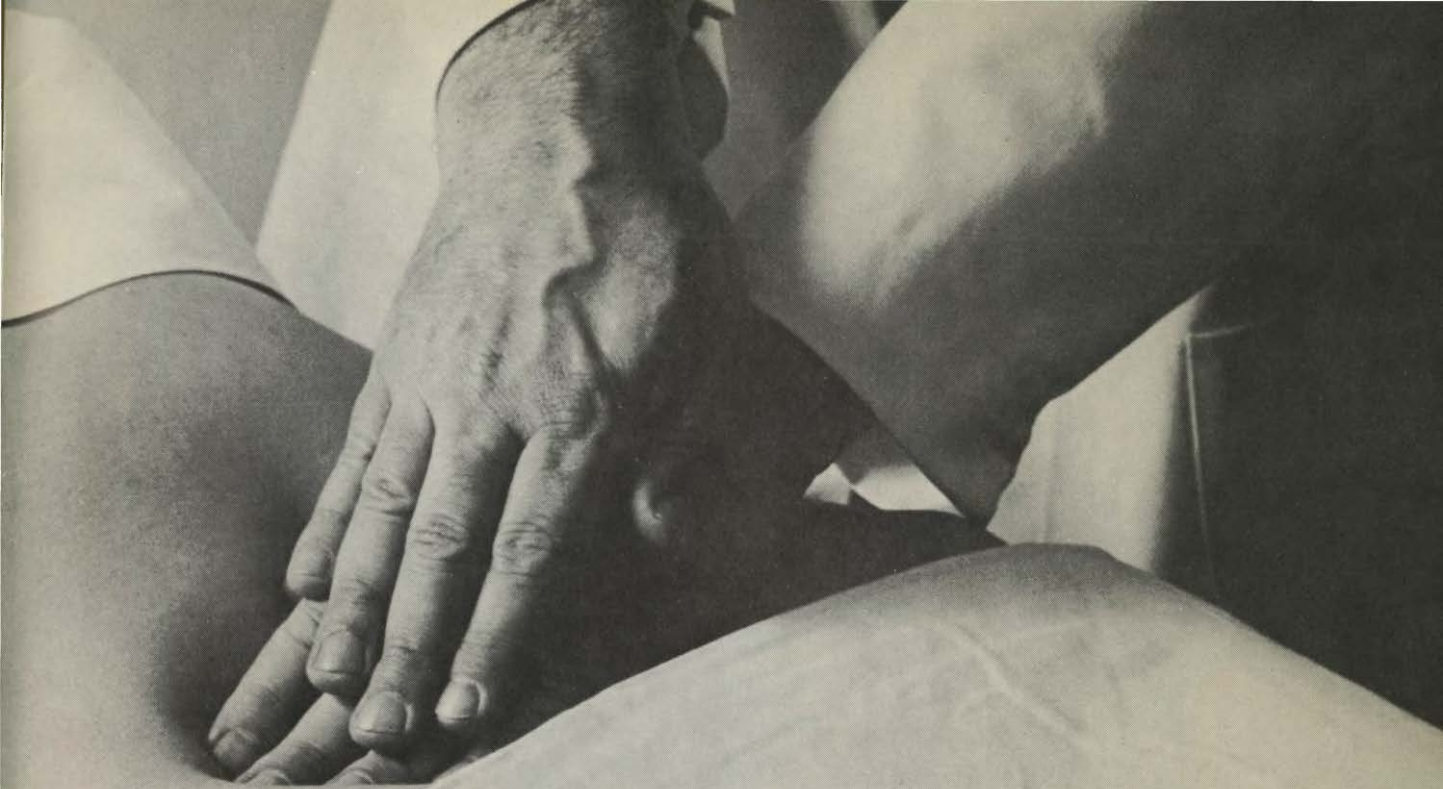Spasm reactor? Donnatal!

| | each tablet, capsule or 5 cc. teaspoonful of elixir (23% alcohol) | each Donnatal No. 2 | each Extentab |
|-----------------------|---|---------------------------|--------------------|
| hyoscine sulfate | 0.1037 mg. | 0.1037 mg. | 0.3111 mg. |
| atropine sulfate | 0.0194 mg. | 0.0194 mg. | 0.0582 mg. |
| hyoscine hydrobromide | 0.0065 mg. | 0.0065 mg. | 0.0195 mg. |
| phenobarbital | (1/4 gr.) 16.2 mg. | (1/2 gr.) 32.4 mg. | (3/4 gr.) 48.6 mg. |

(warning: may be habit forming)

Brief summary. Adverse Reactions: Blurring of vision, dry mouth, difficult urination, and flushing or dryness of the skin may occur on higher dosage levels, rarely on usual dosage. Contraindications: Glaucoma; renal or hepatic disease; obstructive uropathy (for example, bladder neck obstruction due to prostatic hypertrophy); or hypersensitivity to any of the ingredients.

A-H-ROBINS A. H. Robins Company, Richmond, Virginia 23220



Spasm reactor? Donnatal!

| | each tablet, capsule or 5 cc. teaspoonful of elixir (23% alcohol) | each Donnatal No. 2 | each Extentab |
|-----------------------|---|-------------------------------|-------------------------------|
| hyoscyamine sulfate | 0.1037 mg. | 0.1037 mg. | 0.3111 mg. |
| atropine sulfate | 0.0194 mg. | 0.0194 mg. | 0.0582 mg. |
| hyoscine hydrobromide | 0.0065 mg. | 0.0065 mg. | 0.0195 mg. |
| phenobarbital | ($\frac{1}{4}$ gr.) 16.2 mg. | ($\frac{1}{2}$ gr.) 32.4 mg. | ($\frac{3}{4}$ gr.) 48.6 mg. |

(warning: may be habit forming)

Brief summary. Adverse Reactions: Blurring of vision, dry mouth, difficult urination, and flushing or dryness of the skin may occur on higher dosage levels, rarely on usual dosage. Contraindications: Glaucoma; renal or hepatic disease; obstructive uropathy (for example, bladder neck obstruction due to prostatic hypertrophy); or hypersensitivity to any of the ingredients.

A-H-ROBINS A. H. Robins Company, Richmond, Virginia 23220

Before prescribing, please consult complete product information, a summary of which follows:

Indications: Tension and anxiety states, somatic complaints which are concomitants of emotional factors; psychoneurotic states manifested by tension, anxiety, apprehension, fatigue, depressive symptoms or agitation; symptomatic relief of acute agitation, tremor, delirium tremens and hallucinosis due to acute alcohol withdrawal; adjunctively in skeletal muscle spasm due to reflex spasm to local pathology, spasticity caused by upper motor neuron disorders, athetosis, stiff-man syndrome, convulsive disorders (not for sole therapy).

Contraindicated: Known hypersensitivity to the drug. Children under 6 months of age. Acute narrow angle glaucoma; may be used in patients with open angle glaucoma who are receiving appropriate therapy.

Warnings: Not of value in psychotic patients. Caution against hazardous occupations requiring complete mental alertness. When used adjunctively in convulsive disorders, possibility of increase in frequency and/or severity of grand mal seizures may require increased dosage of standard anticonvulsant medication; abrupt withdrawal may be associated with temporary increase in frequency and/or severity of seizures. Advise against simultaneous ingestion of alcohol and other CNS depressants. Withdrawal symptoms (similar to those with barbiturates and alcohol) have occurred following abrupt discontinuance (convulsions, tremor, abdominal and muscle cramps, vomiting and sweating). Keep addiction-prone individuals under careful surveillance because of their predisposition to habituation and dependence. In pregnancy, lactation or women of childbearing age, weigh potential benefit against possible hazard.

Precautions: If combined with other psychotropics or anticonvulsants, consider carefully pharmacology of agents employed; drugs such as phenothiazines, narcotics, barbiturates, MAO inhibitors and other antidepressants may potentiate its action. Usual precautions indicated in patients severely depressed, or with latent depression, or with suicidal tendencies. Observe usual precautions in impaired renal or hepatic function. Limit dosage to smallest effective amount in elderly and debilitated to preclude ataxia or oversedation.

Side Effects: Drowsiness, confusion, diplopia, hypotension, changes in libido, nausea, fatigue, depression, dysarthria, jaundice, skin rash, ataxia, constipation, headache, incontinence, changes in salivation, slurred speech, tremor, vertigo, urinary retention, blurred vision. Paradoxical reactions such as acute hyperexcited states, anxiety, hallucinations, increased muscle spasticity, insomnia, rage, sleep disturbances, stimulation have been reported; should these occur, discontinue drug. Isolated reports of neutropenia, jaundice; periodic blood counts and liver function tests advisable during long-term therapy.

If there's good reason to prescribe for psychic tension...



When, for example, despite counseling,
tension and anxiety continue to produce
distressing somatic symptoms

Prompt action
is a good reason to
consider Valium[®]
(diazepam)

2-mg, 5-mg, 10-mg tablets



Roche Laboratories
Division of Hoffmann-La Roche Inc.
Nutley, N.J. 07110